



### Inspection Report

Dan Moulton  
976 14th Avenue S W  
Rochester, MN 55902

Customer ID: **2401**  
Certificate: **41-B-0239**  
Site: 001  
DAN MOULTON  
  
Type: --RESCINDED--  
Date: 12-FEB-2018

**2.40(b)(2) DIRECT REPEAT**

**ATTENDING VETERINARIAN AND ADEQUATE VETERINARY CARE (DEALERS AND EXHIBITORS).**

There were 12 animals that the facility had identified and developed a treatment plan with the attending veterinarian (AV) on 2-11-18 when the AV visited the facility and looked at the breeder chinchillas. However, during the inspection there were 9 chinchillas that we recognized having health problems and pointed these problems out to the licensee. These 9 chinchillas' active health problems were not recognized prior to inspection and were not receiving any medical treatment at the time of inspection:

- A white female chinchilla's (eartag RVW 109) left eye was swollen shut and had some pale discharge. The eyelids were reddened and the surface of the eyeball had some pale material that appeared adhered to it.
- A beige male that had a large wound on top of his head. The facility was not aware of when it was wounded but reports sometime probably within the past two weeks when he was put in to breed.
- A male grey (eartag DJM 115) chinchilla's left eye was sealed shut with a pale crusty material. The licensee removed the material and its eye had some discharge and the left eyelids were noted to be missing hair, swollen, and red.
- A female grey chinchilla (no eartag; enclosure 59B) had a large red swollen area under its neck.
- A grey female had a swollen, hairless, reddened area under the left side of her jaw.
- A grey female chinchilla (eartag PMR 683) was noticed to have crusted hair around her collar. The licensee gently removed the collar and there was pale discharge with a putrid odor and the skin was swollen and eroded on her lower neck.
- A silver female chinchilla (eartag GROS 214) was shown to us as being treated for an eye problem and considered resolved awhile ago per the licensee and so no longer under treatment but on closer observation we found her left eye was swollen and had some pale discharge. The eyeball was reddened on the surface and the eyelids were swollen. These are signs that her condition is still an active problem.

These direct non-compliances are serious active health problems and if not treated can lead to worsening animal health and discomfort. The facility must have the attending veterinarian evaluate these animals and follow the

**Prepared By:** \_\_\_\_\_  
WELCH SCOTT, D.V.M    USDA, APHIS, Animal Care

**Date:**  
12-FEB-2018

**Title:** VETERINARY MEDICAL OFFICER 6046

**Received By:** \_\_\_\_\_  
DAN MOULTON

**Date:**  
12-FEB-2018

**Title:** LICENSEE  
20-06067\_000029



### Inspection Report

---

recommended treatment.

Non-direct compliances:

-A female grey chinchilla's (no eartag) right eye was crusted shut. The licensee handled it and it was opened and had some pale discharge in it.

-A female grey chinchilla's (eartag DJM 122) left eye was crusted shut. The licensee handled it and it was opened and had some pale discharge in it.

Eye problems if not treated can worsen and possibly spread to other animals and cause animals discomfort. Ensure that the attending veterinarian evaluates these animals and provide them the recommended treatment.

**3.125(a) DIRECT REPEAT**

**FACILITIES, GENERAL.**

An enclosure with two chinchillas had a hole with sharp points. The hole was big enough that the chinchillas possibly could have escaped or fallen out. Large holes in enclosures with sharp points could allow serious injury to animals.

Non-direct non-compliances:

The facility had two other enclosures with holes in the bottoms of the enclosures. The holes had sharp points protruding into the enclosures. In addition, four feeders were observed to have jagged edges with sharp points protruding out. Holes with sharp points and feeders with jagged edges can result in injuries to the chinchillas.

The enclosures and feeders must be maintained in good repair to prevent animal injury.

Note: These enclosures were repaired by the licensee during the inspection and the facility demonstrated that feeders are in the process of being replaced. The facility must ensure to maintain enclosures free from sharp points, large holes, and jagged edges.

This inspection and exit interview were conducted with the licensee.

End of report.

---

**Prepared By:**

WELCH SCOTT, D.V.M    USDA, APHIS, Animal Care

**Date:**  
12-FEB-2018

**Title:** VETERINARY MEDICAL OFFICER 6046

**Received By:**

DAN MOULTON

**Date:**  
12-FEB-2018

**Title:** LICENSEE  
20-06067\_000030



## Inspection Report

---

### Additional Inspectors

Wilken Kevin, Animal Care Inspector

---

### Prepared By:

WELCH SCOTT, D.V.M    USDA, APHIS, Animal Care

**Date:**  
12-FEB-2018

**Title:** VETERINARY MEDICAL OFFICER 6046

### Received By:

DAN MOULTON

**Date:**  
12-FEB-2018

**Title:** LICENSEE  
20-06067\_000031

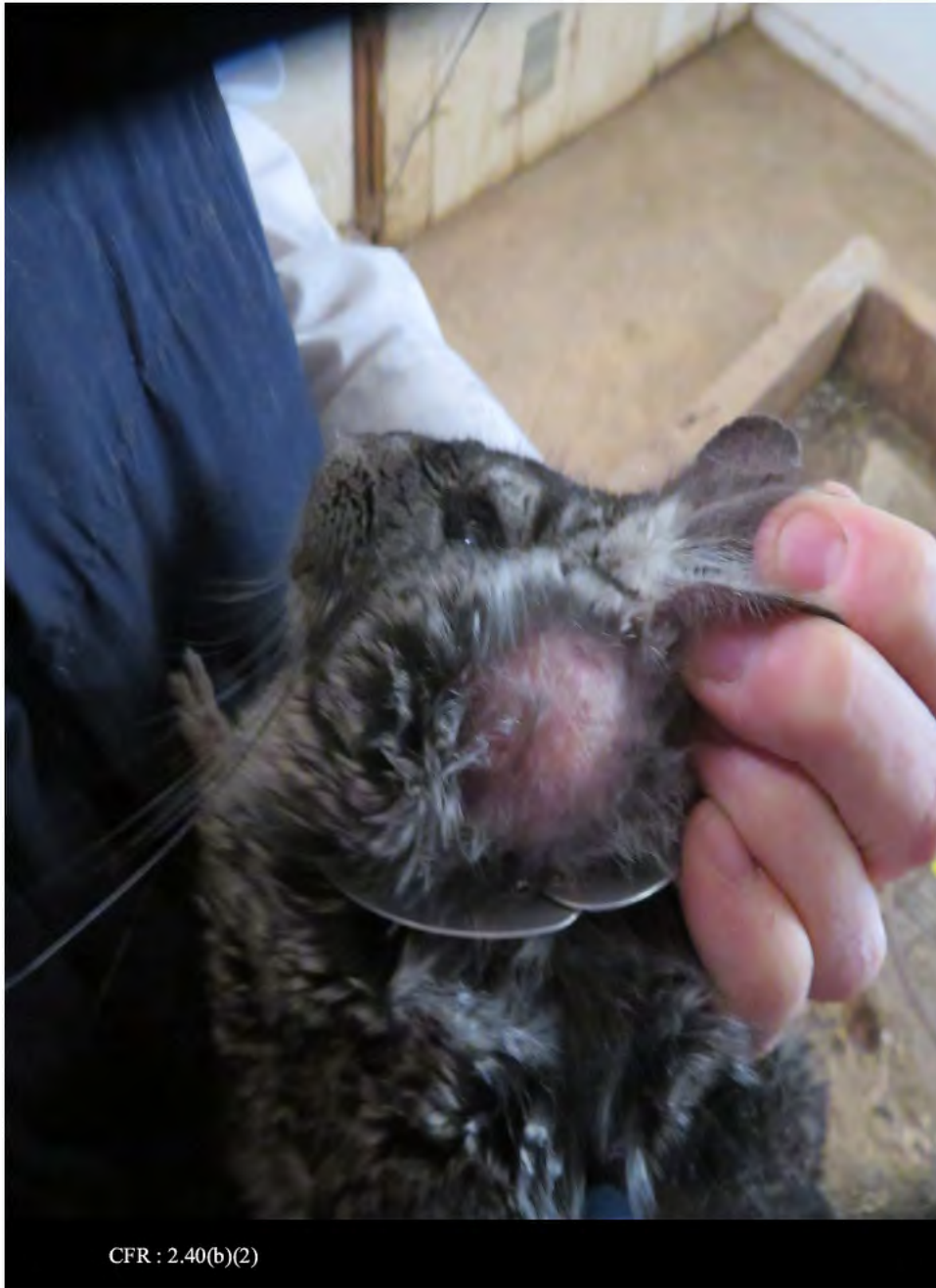

### Species Inspected

--RESCINDED--

Cust No	Cert No	Site	Site Name	Inspection
2401	41-B-0239	001	DAN MOULTON	12-FEB-18

Count	Scientific Name	Common Name
000516	<i>Chinchilla lanigera</i>	CHINCHILLA (DOMESTICATED)
<b>000516</b>	<b>Total</b>	



CFR : 2.40(b)(2)

---

**Photographer:** SCOTT WELCH

**Date and Time:** 12-FEB-18

**Inspection No:** 2016082569049787

**Description:**

Female grey chinchilla with a swollen area under her left side of her jaw. Facility assigned her treatment tag #65 after we pointed the problem out.

**Certificate:** 41-B-0239

**Legal Name:**

**DAN MOULTON**



CFR : 2.40(b)(2)

---

**Photographer:** SCOTT WELCH

**Date and Time:** 12-FEB-18

**Inspection No:** 2016082569049787

**Description:**

Female grey chinchilla with a swollen area under her left side of her jaw. Facility assigned her treatment tag #65 after we pointed the problem out. Picture is taken looking at chinchilla from above.

**Certificate:** 41-B-0239

**Legal Name:**

**DAN MOULTON**



CFR : 2.40(b)(2)

---

**Photographer:** SCOTT WELCH

**Date and Time:** 12-FEB-18

**Inspection No:** 2016082569049787

**Description:**

Female grey chinchilla with a swollen area under her left side of her jaw. Facility assigned her treatment tag #65 after we pointed the problem out. Picture is looking at chinchilla from front of enclosure.

**Certificate:** 41-B-0239

**Legal Name:**

**DAN MOULTON**



CFR : 2.40(b)(2)

---

**Photographer:** SCOTT WELCH

**Date and Time:** 12-FEB-18

**Inspection No:** 2016082569049787

**Description:**

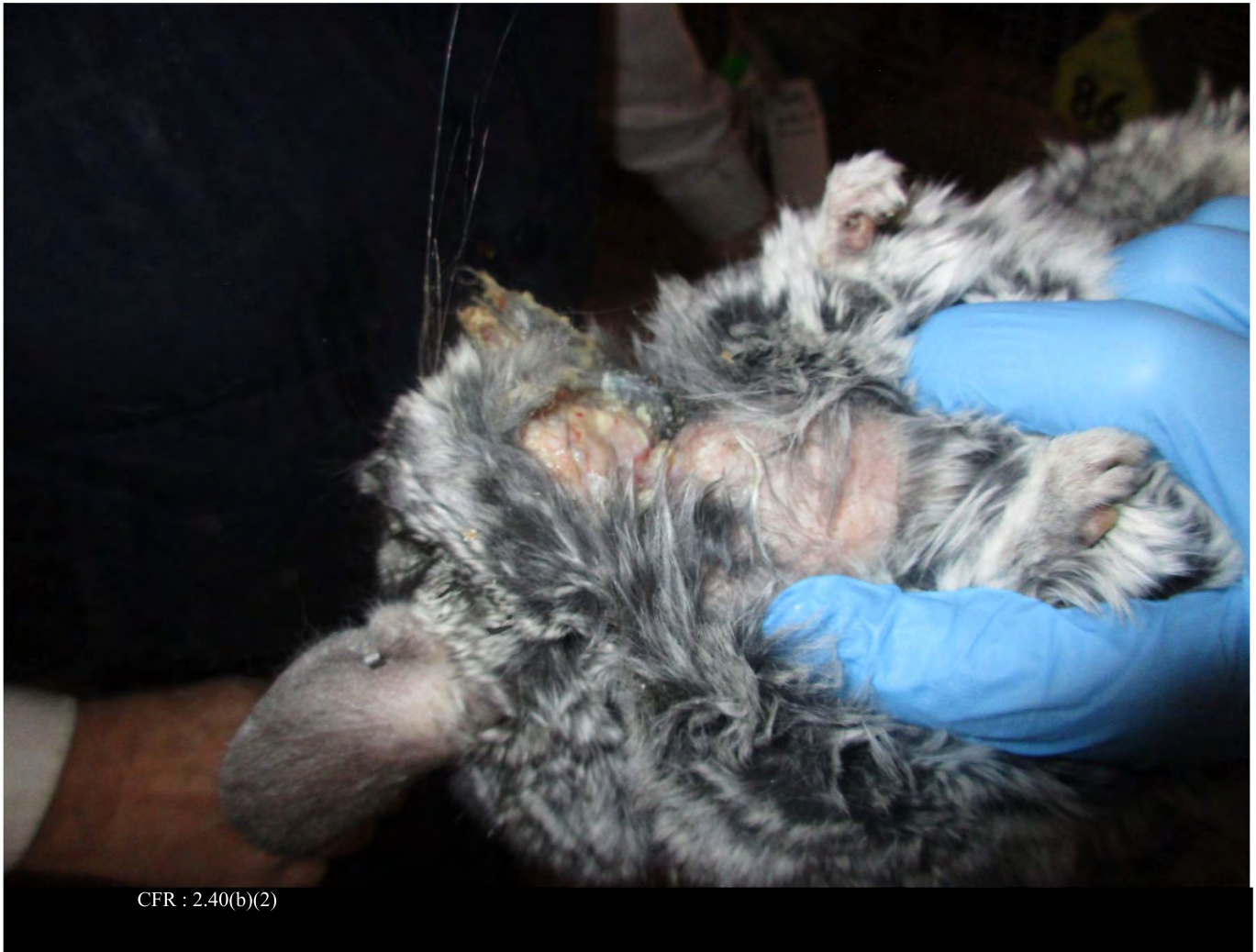Female grey chinchilla with a swollen area under her left side of her jaw. Facility assigned her treatment tag #65 after we pointed the problem out. Picture is looking at chinchilla from the front of the enclosure.

**Certificate:** 41-B-0239

**Legal Name:**

**DAN MOULTON**





---

**Photographer:** KEVIN WILKEN

**Date and Time:** 12-FEB-18

**Inspection No:** 2016082569049787

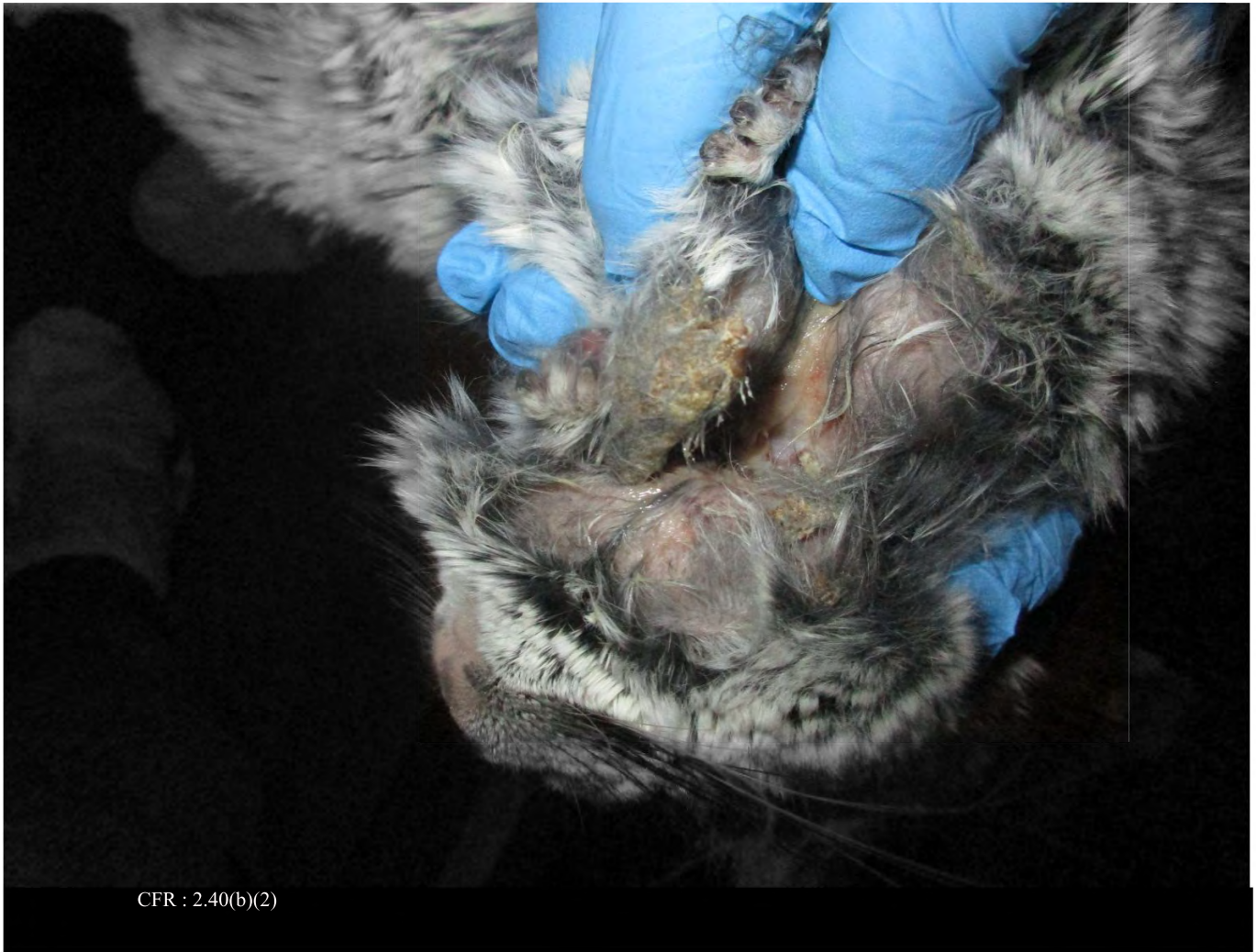**Description:**

Ventral neck (lower neck) of chinchilla (eartag PMR 683) that had swollen skin and eroded skin under where collar was. Discharge can be seen in center of hairless area.

**Certificate:** 41-B-0239

**Legal Name:**

**DAN MOULTON**



CFR : 2.40(b)(2)

---

**Photographer: KEVIN WILKEN**

**Date and Time: 12-FEB-18**

**Inspection No: 2016082569049787**

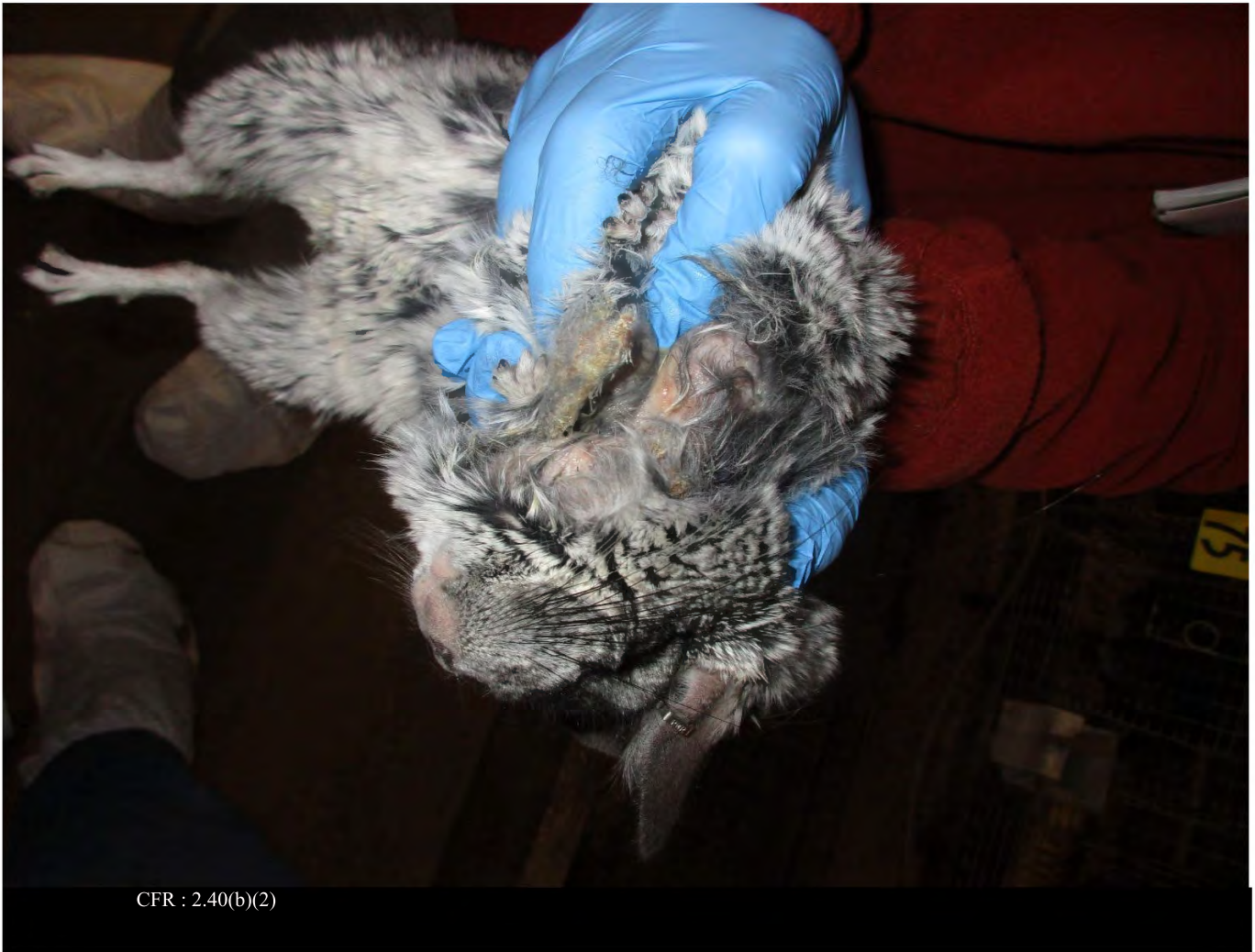**Description:**

Ventral neck (lower neck) of chinchilla (eartag PMR 683) that had crusted hair around collar and found to have swollen skin and eroded skin under where collar was.

**Certificate: 41-B-0239**

**Legal Name:**

**DAN MOULTON**



CFR : 2.40(b)(2)

---

**Photographer: KEVIN WILKEN**

**Date and Time: 12-FEB-18**

**Inspection No: 2016082569049787**

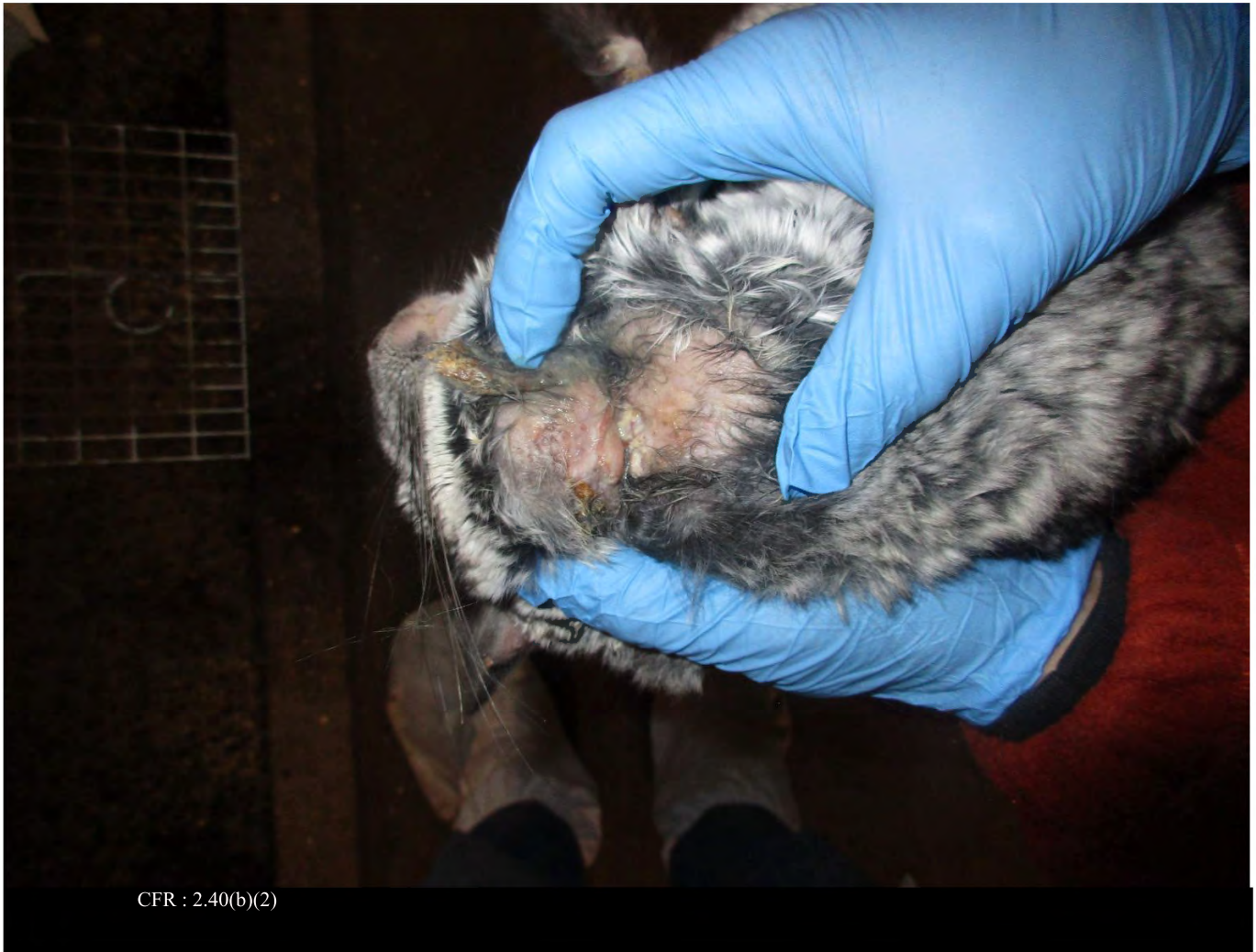**Description:**

Ventral neck (lower neck) of chinchilla (eartag PMR 683) that had swollen skin and eroded area under where collar was.

**Certificate: 41-B-0239**

**Legal Name:**

**DAN MOULTON**



CFR : 2.40(b)(2)

---

**Photographer: KEVIN WILKEN**

**Date and Time: 12-FEB-18**

**Inspection No: 2016082569049787**

**Description:**

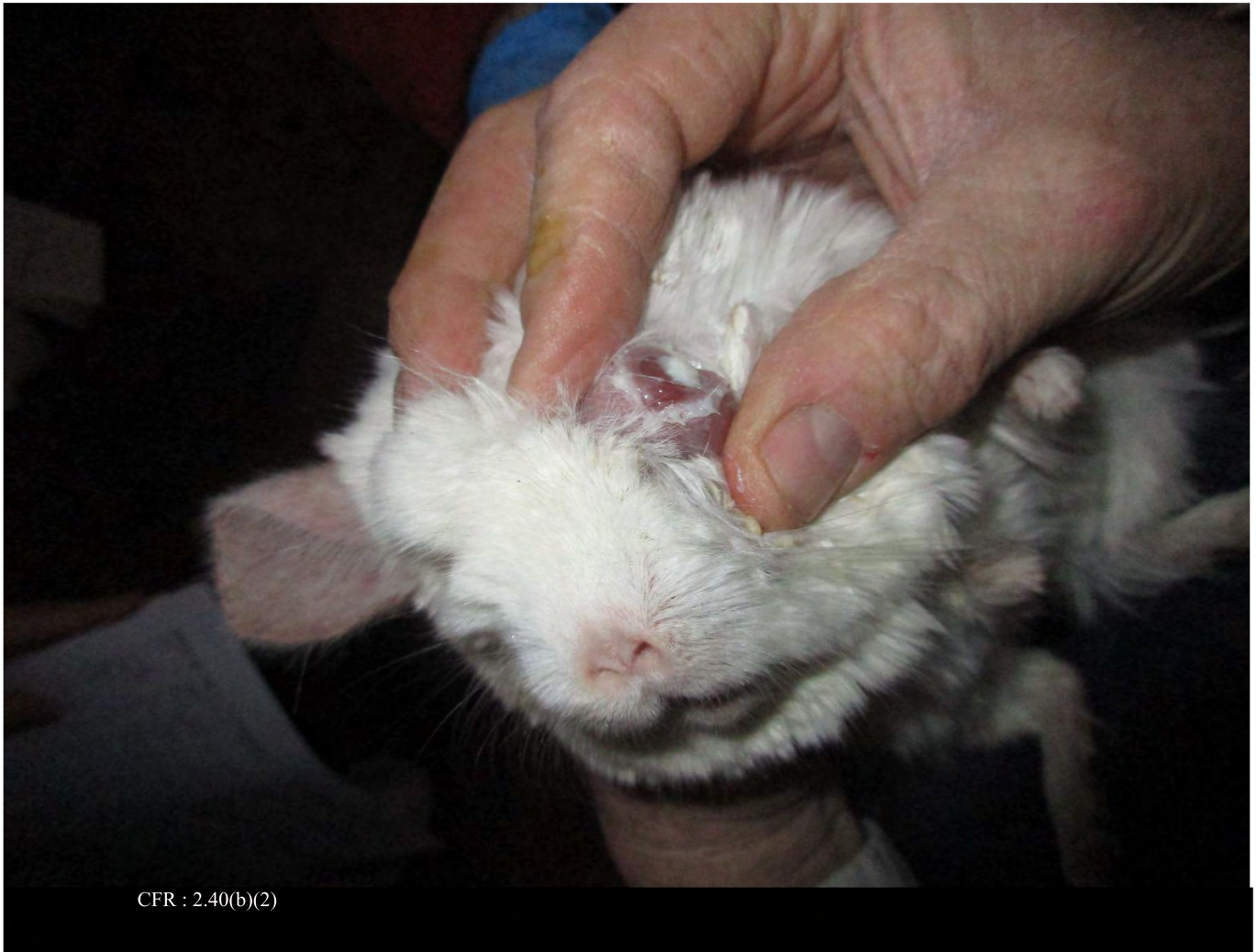Ventral neck (lower neck) of chinchilla (eartag PMR 683) that had swollen skin, and eroded skin under collar with noticeable putrid odor on her lower neck.

Discharge can be seen in hairless area.

**Certificate: 41-B-0239**

**Legal Name:**

**DAN MOULTON**



CFR : 2.40(b)(2)

---

**Photographer: KEVIN WILKEN**

**Date and Time: 12-FEB-18**

**Inspection No: 2016082569049787**

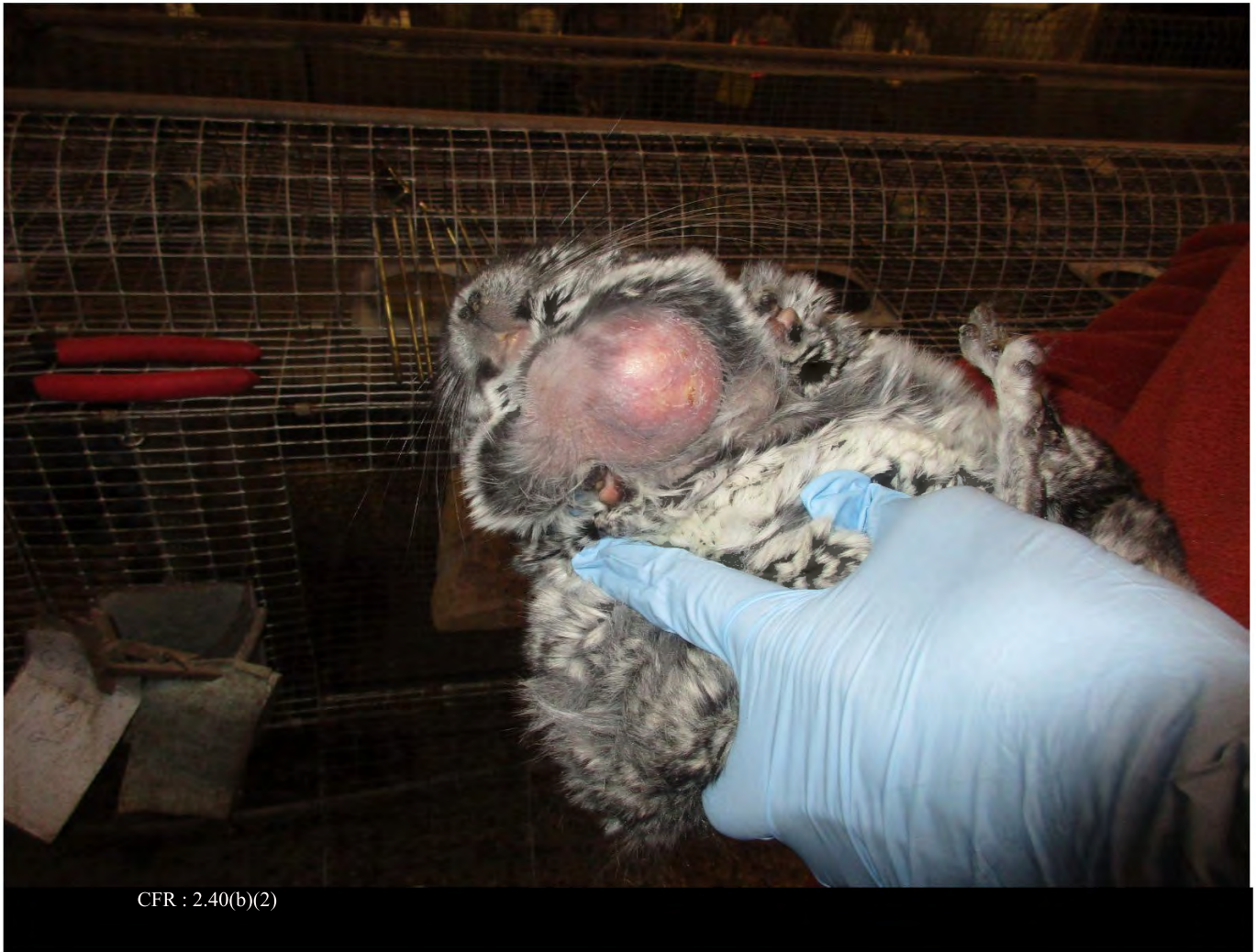**Description:**

Female white (cartag RVW 109) chinchilla's left eye was swollen shut and when handled by licensee had some pale discharge.

**Certificate: 41-B-0239**

**Legal Name:**

**DAN MOULTON**



---

**Photographer:** KEVIN WILKEN

**Date and Time:** 12-FEB-18

**Inspection No:** 2016082569049787

**Description:**

Grey female chinchilla (no tag, housed in 59B) had a swollen, red, hairless area under her neck.

**Certificate:** 41-B-0239

**Legal Name:**

**DAN MOULTON**



CFR : 3.125(a)

---

**Photographer:** KEVIN WILKEN

**Date and Time:** 12-FEB-18

**Inspection No:** 2016082569049787

**Description:**

Wire points protruding from divider in front of chinchilla.

**Certificate:** 41-B-0239

**Legal Name:**

**DAN MOULTON**



CFR : 3.125(a)

---

**Photographer:** SCOTT WELCH

**Date and Time:** 12-FEB-18

**Inspection No:** 2016082569049787

**Description:**

Hole in floor of enclosure with sharp points creating escape/injury hazards.

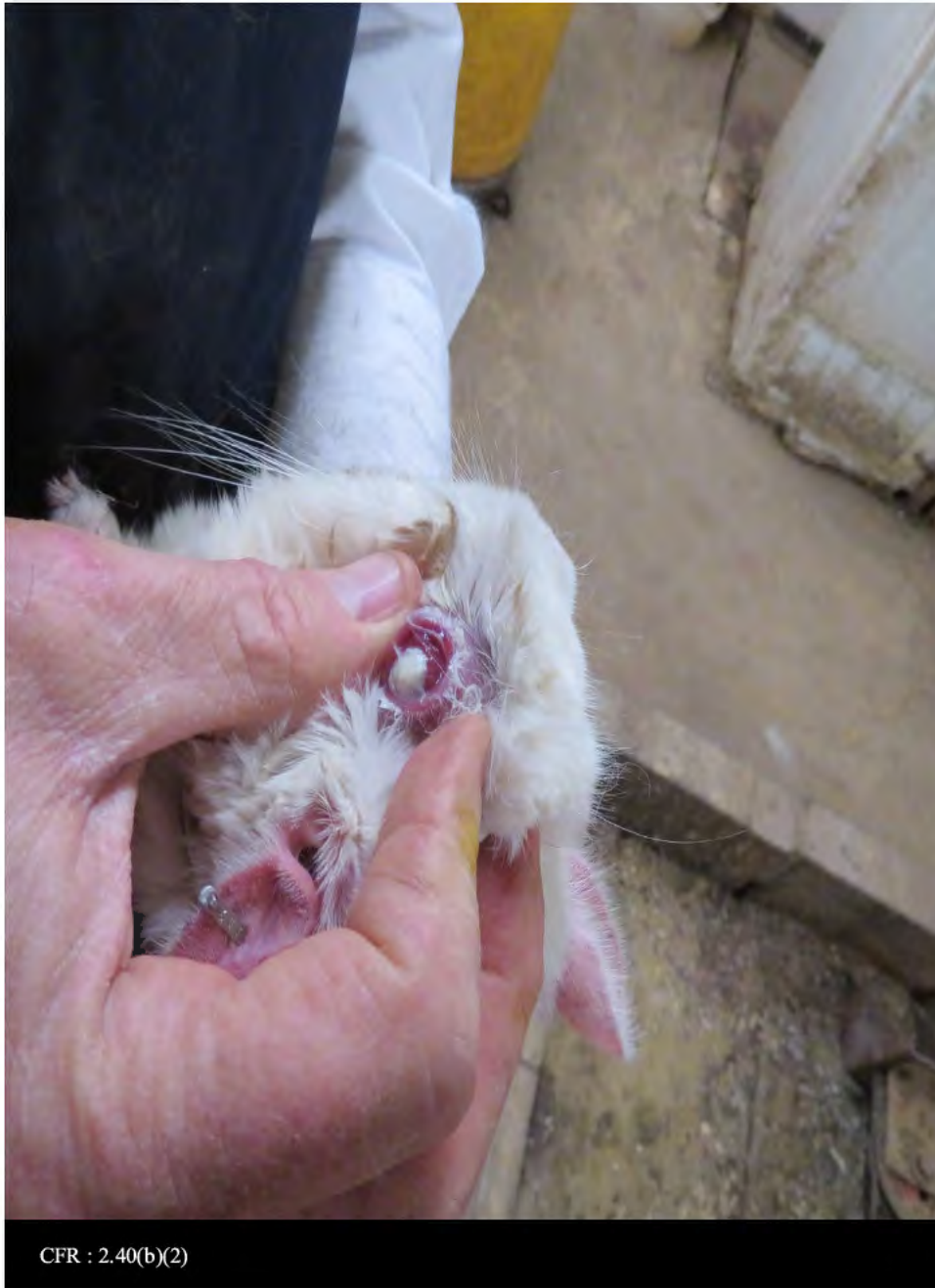Licensee patched hole and removed points during inspection.

**Certificate:** 41-B-0239

**Legal Name:**

**DAN MOULTON**





CFR : 2.40(b)(2)

---

**Photographer: SCOTT WELCH**

**Date and Time: 12-FEB-18**

**Inspection No: 2016082569049787**

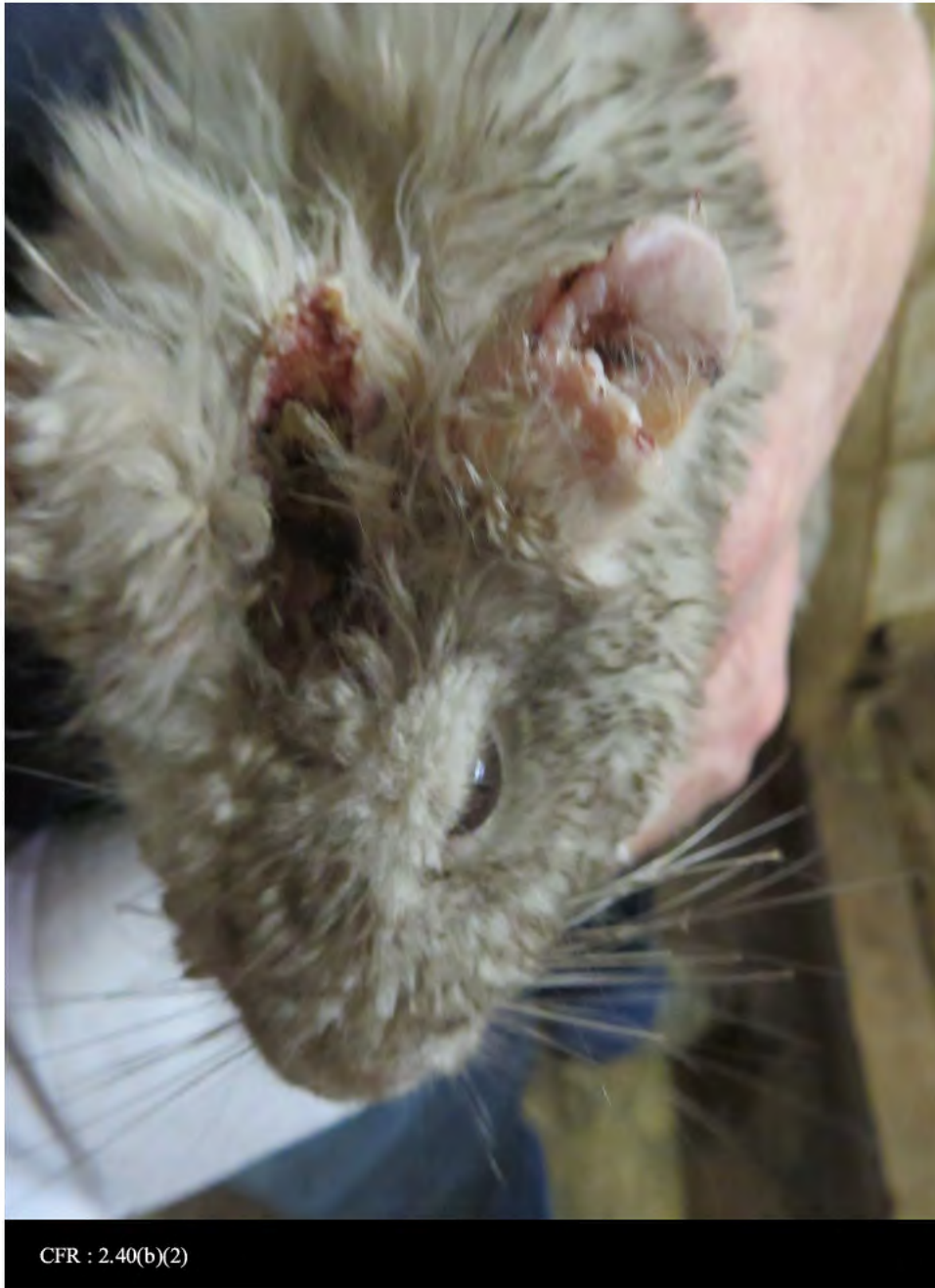**Description:**

Female white (eartag RVW 109) chinchilla's left eye was swollen shut and when handled by licensee had some pale discharge; the pale material in the center surface of the eyeball (seen in photo) appeared adhered to it while the licensee handled it.

**Certificate: 41-B-0239**

**Legal Name:**

**DAN MOULTON**



CFR : 2.40(b)(2)

---

**Photographer:** SCOTT WELCH

**Date and Time:** 12-FEB-18

**Inspection No:** 2016082569049787

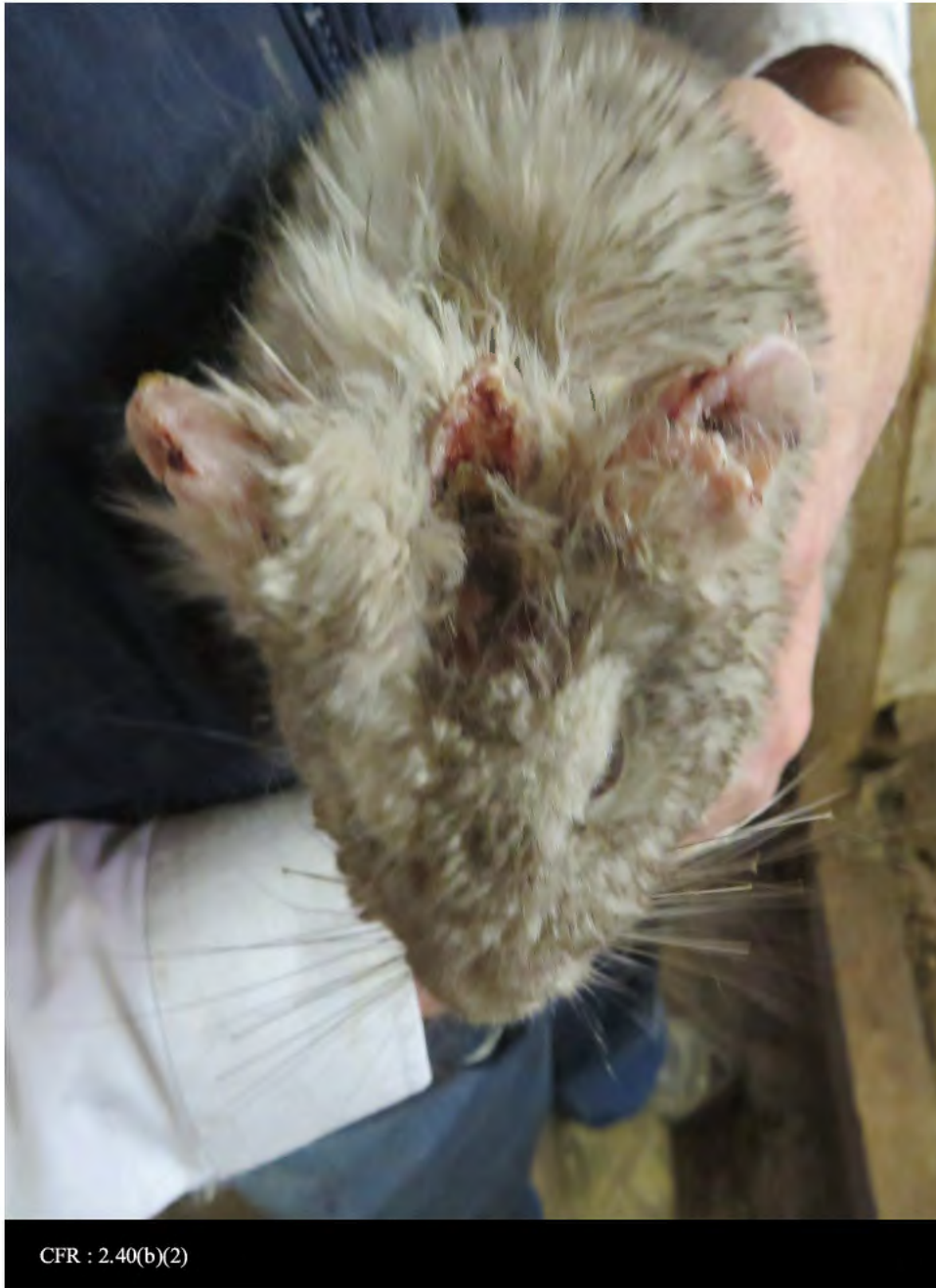
**Description:**

Male chinchilla (no eartag, housed in bank 101) open wound on top of head.

**Certificate:** 41-B-0239

**Legal Name:**

**DAN MOULTON**



CFR : 2.40(b)(2)

---

**Photographer:** SCOTT WELCH

**Date and Time:** 12-FEB-18

**Inspection No:** 2016082569049787

**Description:**

Male chinchilla (no eartag, housed in bank 101) open wound on top of head.

**Certificate:** 41-B-0239

**Legal Name:**

**DAN MOULTON**



CFR : 2.40(b)(2)

---

**Photographer:** SCOTT WELCH

**Date and Time:** 12-FEB-18

**Inspection No:** 2016082569049787

**Description:**

A female grey (eartag DJM 122) chinchilla's left eye was crusted shut; the licensee opened it and there was some pale discharge in it.

**Certificate:** 41-B-0239

**Legal Name:**

**DAN MOULTON**



CFR : 2.40(b)(2)

---

**Photographer:** SCOTT WELCH

**Date and Time:** 12-FEB-18

**Inspection No:** 2016082569049787

**Description:**

Male grey (eartag DJM 115) chinchilla's left eye seen while licensee removed crusted material--discharge present and note reddened, hairless eyelids.

**Certificate:** 41-B-0239

**Legal Name:**

**DAN MOULTON**



CFR : 2.40(b)(2)

---

**Photographer:** SCOTT WELCH

**Date and Time:** 12-FEB-18

**Inspection No:** 2016082569049787

**Description:**

Grey female chinchilla (no tag, housed in 59B) had a swollen, red, hairless area under her neck.

**Certificate:** 41-B-0239

**Legal Name:**

**DAN MOULTON**



CFR : 3.125(a)

---

**Photographer:** SCOTT WELCH

**Date and Time:** 12-FEB-18

**Inspection No:** 2016082569049787

**Description:**

Hole in floor of enclosure with sharp points creating escape/injury hazards.

Licensee patched hole and removed points during inspection.

**Certificate:** 41-B-0239

**Legal Name:**

**DAN MOULTON**



CFR : 3.125(a)

---

**Photographer:** SCOTT WELCH

**Date and Time:** 12-FEB-18

**Inspection No:** 2016082569049787

**Description:**

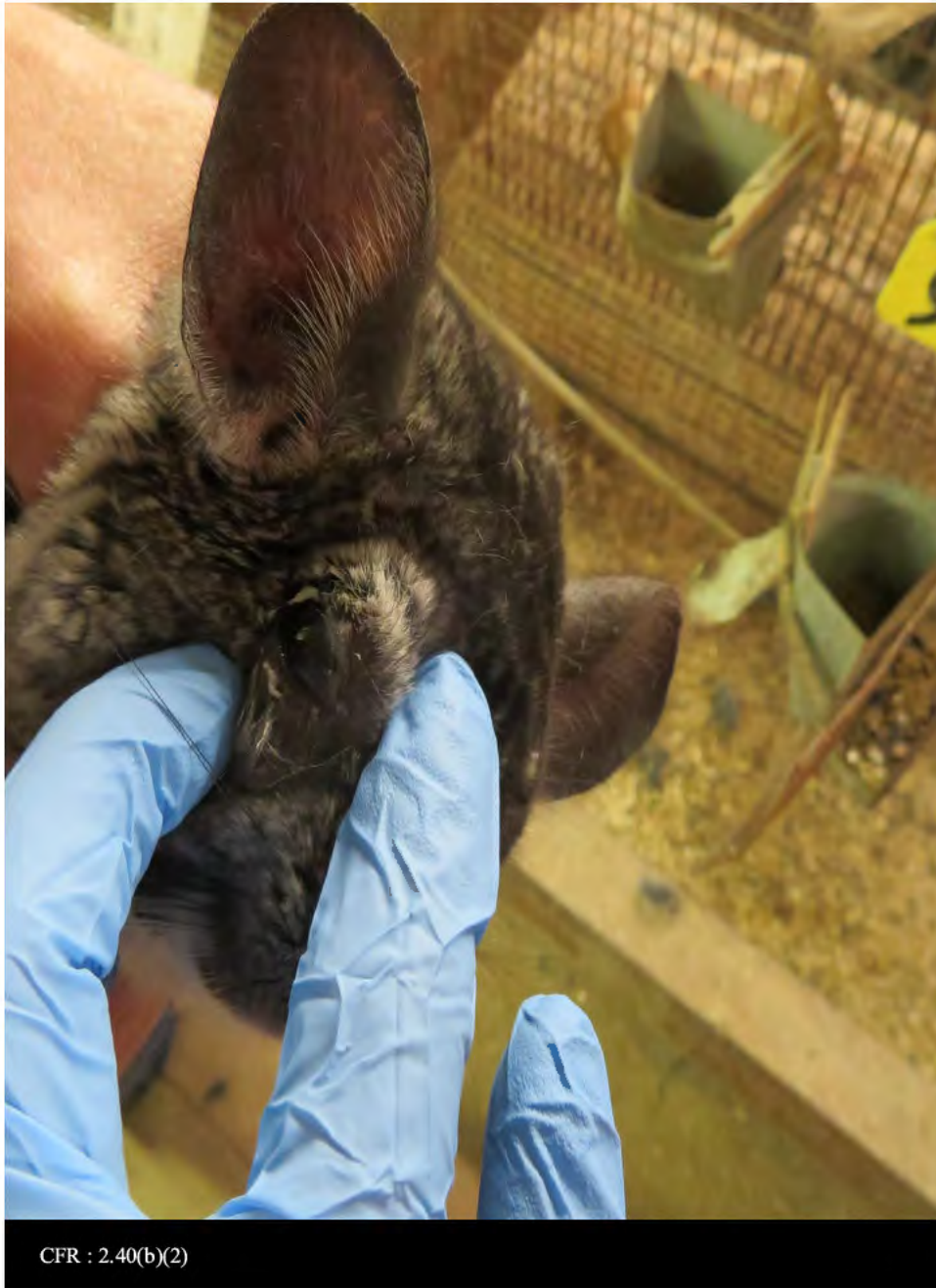Broken wire on floor (center of image). Licensee removed broken wire and patched hole during inspection.

**Certificate:** 41-B-0239

**Legal Name:**

**DAN MOULTON**





CFR : 2.40(b)(2)

---

**Photographer:** SCOTT WELCH

**Date and Time:** 12-FEB-18

**Inspection No:** 2016082569049787

**Description:**

Female grey (no eartag, housed in 90A) chinchilla's right eye was crusted shut and had some discharge.

**Certificate:** 41-B-0239

**Legal Name:**

**DAN MOULTON**



CFR : 2.40(b)(2)

---

**Photographer:** SCOTT WELCH

**Date and Time:** 12-FEB-18

**Inspection No:** 2016082569049787

**Description:**

Male grey (eartag DJM 115) chinchilla's left eye sealed shut with a pale crusted material, taken prior to licensee removing crusted material.

**Certificate:** 41-B-0239

**Legal Name:**

**DAN MOULTON**



CFR : 2.40(b)(2)

---

**Photographer:** SCOTT WELCH

**Date and Time:** 12-FEB-18

**Inspection No:** 2016082569049787

**Description:**

Chinchilla (eartag GROS 214) with discharge in her left eye.

**Certificate:** 41-B-0239

**Legal Name:**

**DAN MOULTON**



CFR : 2.40(b)(2)

---

**Photographer:** SCOTT WELCH

**Date and Time:** 12-FEB-18

**Inspection No:** 2016082569049787

**Description:**

Close-up of GROS 214's left eye; swelling present and surface of eye is reddened.

**Certificate:** 41-B-0239

**Legal Name:**

**DAN MOULTON**