



Inspection Report

DAN MOULTON

Customer ID: **2401**

Certificate: **41-B-0239**

Site: 001

DAN MOULTON

MOULTONS CHINCHILLA RANCH

976 14TH AVENUE S W

Type: --RESCINDED--

ROCHESTER, MN 55902

Date: Jun-22-2016

2.40 (b) (2) REPEAT DIRECT NCI

ATTENDING VETERINARIAN AND ADEQUATE VETERINARY CARE (DEALERS AND EXHIBITORS).

Multiple chinchillas had health problems that had not been recognized by the facility and were not receiving any medical treatment:

-Male grey (no id; housed in south stacked cages, west/front room) had a large hairless swelling under its chin and its right eye was crusted shut and had hair loss around it with a creamy pale discharge.

-Female grey with ear tag 332; its right eye was swollen and had a pale creamy discharge.

-Female black with ear tag GROS 313 had a soiled and unkempt hair coat, crusty eyes and hair loss around the lower jaw area. The licensee said that it appeared to have 'bone spurs' on the bottom jaw and may have bad back teeth. The combination of an unkempt hair coat, crusty eyes, and hair loss are suggestive of an underlying health condition that must be determined by the attending veterinarian and treated per the AV's recommendations.

-Male beige with ear tag GROS 329; its left eye was swollen and had a pale creamy discharge in it.

-Male beige (no ID; cage card "AMMC"); its left eye was swollen and had a pale creamy discharge in it.

-Male cream with ear tag GROS 375; had a large, hairless swelling under its chin that was firm and had reddened skin indicating inflammation. The chinchilla would vocalize each time the swelling was lightly touched indicating the swelling was painful.

-Female beige with ear tag GROS 352 had a large hairless swelling on the area under its chin.

INDIRECT NON-COMPLIANCES:

-White female in cage 168 on south stacked cages, tag 876 had a swollen area with hair-loss and the tissues felt thickened. Licensee said that this was just a 'plump' chinchilla. Given the other chinchillas with concerning chin swellings, the licensee must have this chinchilla observed by the veterinarian to determine if any treatment is necessary.

Prepared By:

SCOTT M WELCH, VMO USDA, APHIS, Animal Care

Date:

Title: VETERINARY MEDICAL OFFICER Inspector 6046

Jun-23-2016

Received By:

DAN MOULTON

Date:

Title: OWNER

Jun-22-2016



Inspection Report

-Female grey with ear tag PMR 233; its left eye had an opaque mass inside of its eyeball. To ensure that this condition is not painful, the licensee must have the attending veterinarian observe this animal's condition and follow any treatment instructions.

-Silver grey female (no ID, housed in front room, north side, row of cages facing the wall); had a left head tilt and when it moved, it would circle to its left. The licensee reports observing this problem about two months ago and has been observing it for improvement but the attending veterinarian has not been consulted to diagnose and guide any treatment for this animal.

****Untreated medical problems can cause ongoing pain in affected animals and can be contagious to other animals in the building. The veterinarian must be contacted to properly diagnose and treat each animal's health problem and the facility must follow the recommended treatment. Documentation of the diagnosis and treatment plan for animals must be available for APHIS officials for future inspections.**

2.40 (b) (3) DIRECT NCI

ATTENDING VETERINARIAN AND ADEQUATE VETERINARY CARE (DEALERS AND EXHIBITORS).

The facility had previously recognized and had 10 chinchillas under treatment with eye problems at the time of inspection, but there were 9 more chinchillas that had health problems that we brought to the licensee's attention during inspection. These 9 chinchillas were pointed out to the licensee by inspectors to have health conditions:

- Male grey (no id; housed in south stacked cages, west/front room) had a large hairless mass under its chin and its right eye had hair loss around it with a crusty and creamy pale discharge.
- Female grey with ear tag 332; its right eye was swollen and had a pale creamy discharge.
- Female black with ear tag GROS 313 had a soiled and unkempt hair coat, crusty eyes and hair loss around the lower jaw areas.
- Male beige with ear tag GROS 329; its left eye that was swollen and had a pale creamy discharge in it.
- Male beige (no ID; cage card "AMMC"); its left eye was swollen and had a pale creamy discharge in it.
- Male cream colored with ear tag GROS 375; had a large, hairless swelling under its chin that was firm. The chinchilla would vocalize each time the swelling was lightly touched indicating possible pain.

INDIRECT NON-COMPLIANCES:

- Female white in cage 168 on south stacked cages, tag 876 had a swollen area with hair-loss and the tissues felt thickened.
- Female grey with ear tag PMR 233; its left eye had an opaque mass inside of its eyeball.

Lack of thorough daily observations has resulted in animals not receiving prompt veterinary care. The facility must develop and maintain a method of routine daily observations to ensure any animal with a health problem is treated promptly and appropriately.

Prepared By:

SCOTT M WELCH, VMO USDA, APHIS, Animal Care

Date:

Title: VETERINARY MEDICAL OFFICER Inspector 6046

Jun-23-2016

Received By:

DAN MOULTON

Date:

Title: OWNER

Jun-22-2016



Inspection Report

3.125 (a) REPEAT

FACILITIES, GENERAL.

Structural Strength.

Two enclosures had wire points that the animals could contact. Two chinchillas were affected. Sharp metal points inside the enclosure can result in animal injuries. The facility must be maintained in good repair to contain and protect animals from injury.

Note: The licensee corrected the sharp metal points during the inspection.

3.125 (d) REPEAT DIRECT NCI

FACILITIES, GENERAL.

Waste disposal.

The facility's equipment to eliminate the excreta, waste, and used bedding from the gutter was not working properly at the time of inspection. There was a large buildup of excreta, waste, used bedding and water under the enclosures of animals located over the south gutter of the facility. This buildup of material created a strong ammonia smell and foul odor within the facility and a large number of small black flies were present in the middle room of the facility. This buildup of material and foul odors can cause sickness in animals and attract pests such as flies. Eliminate the excessive buildup of excreta, waste, used bedding and excess soiled water from the facility as often as necessary to minimize vermin infestation, odors, and disease hazards.

Note: The licensee reports having contacted the repairman prior to inspection and contacted the repairman during the inspection and scheduled repairs for Sunday 6/26/2016. The licensee must ensure that it is fixed by then. If the equipment breaks down again, additional methods must be used to remove soiled material from the building to protect the animals from excessive odors and disease hazards.

3.130 REPEAT

WATERING.

The water lines that provide water for the majority of the animals have sections where the tubing has a greenish appearance. The outside of the watering line continues to have some areas where an excessive buildup of hair and soiled material is present. At least one watering bottle had a greenish buildup inside of it. Unclean water receptacles may contaminate the water supply and cause many animals to get sick. To protect the health of the animals, clean and/or replace water lines, spouts, and bottles as often as necessary to assure a clean supply of water to the animals.

3.131 (a) REPEAT

SANITATION.

Enclosures in the front room in the middle group pens where about 20 chinchillas are housed and enclosures on the stacked enclosures on the south side of the front room housing approximately 10 chinchillas were noted to have an excessive amount of feces. The licensee stated that the enclosures had

Prepared By:

SCOTT M WELCH, VMO USDA, APHIS, Animal Care

Date:

Title: VETERINARY MEDICAL OFFICER Inspector 6046

Jun-23-2016

Received By:

DAN MOULTON

Date:

Title: OWNER

Jun-22-2016



Inspection Report

Dan Moulton
Moultons Chinchilla Ranch
976 14th Avenue S W
Rochester, MN 55902

Customer ID: **2401**
Certificate: **41-B-0239**
Site: 001
DAN MOULTON

Type: ROUTINE INSPECTION
Date: Jun-22-2016

2.40 (b) (2) **REPEAT DIRECT NCI**
ATTENDING VETERINARIAN AND ADEQUATE VETERINARY CARE (DEALERS AND EXHIBITORS).

Multiple chinchillas had health problems that had not been recognized by the facility and were not receiving any medical treatment:

- Male grey (no id; housed in south stacked cages, west/front room) had a large hairless swelling under its chin and its right eye was crusted shut and had hair loss around it with a creamy pale discharge.
- Female grey with ear tag 332; its right eye was swollen and had a pale creamy discharge.
- Female black with ear tag GROS 313 had a soiled and unkempt hair coat, crusty eyes and hair loss around the lower jaw area. The licensee said that it appeared to have 'bone spurs' on the bottom jaw and may have bad back teeth. The combination of an unkempt hair coat, crusty eyes, and hair loss are suggestive of an underlying health condition that must be determined by the attending veterinarian and treated per the AV's recommendations.
- Male beige with ear tag GROS 329; its left eye was swollen and had a pale creamy discharge in it.
- Male beige (no ID; cage card "AMMC"); its left eye was swollen and had a pale creamy discharge in it.
- Male cream with ear tag GROS 375; had a large, hairless swelling under its chin that was firm and had reddened skin indicating inflammation. The chinchilla would vocalize each time the swelling was lightly touched indicating the swelling was painful.
- Female beige with ear tag GROS 352 had a large hairless swelling on the area under its chin.

INDIRECT NON-COMPLIANCES:

-White female in cage 168 on south stacked cages, tag 876 had a swollen area with hair-loss and the tissues felt thickened. Licensee said that this was just a 'plump' chinchilla. Given the other chinchillas with concerning chin swellings, the licensee must have this chinchilla observed by the veterinarian to determine if any treatment is necessary.

Prepared By: (b) (6), (b) (7)(C)
SCOTT M WELCH, VMO USDA, APHIS, Animal Care

Date:
Jul-08-2016

Title: VETERINARY MEDICAL OFFICER Inspector 6046

Received By: DAN MOULTON; OWNER

Title: CERTIFIED MAIL 7015 3430 0000 1868 5663

Date:
Jul-08-2016



Inspection Report

-Female grey with ear tag PMR 233; its left eye had an opaque mass inside of its eyeball. To ensure that this condition is not painful, the licensee must have the attending veterinarian observe this animal's condition and follow any treatment instructions.

-Silver grey female (no ID, housed in front room, north side, row of cages facing the wall); had a left head tilt and when it moved, it would circle to its left. The licensee reports observing this problem about two months ago and has been observing it for improvement but the attending veterinarian has not been consulted to diagnose and guide any treatment for this animal.

**Untreated medical problems can cause ongoing pain in affected animals and can be contagious to other animals in the building. The veterinarian must be contacted to properly diagnose and treat each animal's health problem and the facility must follow the recommended treatment. Documentation of the diagnosis and treatment plan for animals must be available for APHIS officials for future inspections.

2.40 (b) (3) REPEAT DIRECT NCI

ATTENDING VETERINARIAN AND ADEQUATE VETERINARY CARE (DEALERS AND EXHIBITORS).

The facility had previously recognized and had 10 chinchillas under treatment with eye problems at the time of inspection, but there were 9 more chinchillas that had health problems that we brought to the licensee's attention during inspection. These 9 chinchillas were pointed out to the licensee by inspectors to have health conditions:

- Male grey (no id; housed in south stacked cages, west/front room) had a large hairless mass under its chin and its right eye had hair loss around it with a crusty and creamy pale discharge.
- Female grey with ear tag 332; its right eye was swollen and had a pale creamy discharge.
- Female black with ear tag GROS 313 had a soiled and unkempt hair coat, crusty eyes and hair loss around the lower jaw areas.
- Male beige with ear tag GROS 329; its left eye that was swollen and had a pale creamy discharge in it.
- Male beige (no ID; cage card "AMMC"); its left eye was swollen and had a pale creamy discharge in it.
- Male cream colored with ear tag GROS 375; had a large, hairless swelling under its chin that was firm. The chinchilla would vocalize each time the swelling was lightly touched indicating possible pain.
- Female beige with ear tag GROS 352 had a large hairless swelling on the area under its chin.

INDIRECT NON-COMPLIANCES:

- Female white in cage 168 on south stacked cages, tag 876 had a swollen area with hair-loss and the tissues felt thickened.
- Female grey with ear tag PMR 233; its left eye had an opaque mass inside of its eyeball.

Lack of thorough daily observations has resulted in animals not receiving prompt veterinary care. The facility must develop and maintain a method of routine daily observations to ensure any animal with a health problem is treated promptly and appropriately.

Prepared By: (b) (6), (b) (7)(C)

SCOTT M WELCH, VMO USDA, APHIS, Animal Care

Date:

Title: VETERINARY MEDICAL OFFICER Inspector 6046

Jul-08-2016

Received By:

DAN MOULTON; OWNER

Date:

Title: CERTIFIED MAIL 7015 3430 0000 1868 5663

Jul-08-2016



Inspection Report

3.125 (a) **REPEAT**

FACILITIES, GENERAL.

Structural Strength.

Two enclosures had wire points that the animals could contact. Two chinchillas were affected. Sharp metal points inside the enclosure can result in animal injuries. The facility must be maintained in good repair to contain and protect animals from injury.

Note: The licensee corrected the sharp metal points during the inspection.

3.125 (d) **REPEAT DIRECT NCI**

FACILITIES, GENERAL.

Waste disposal.

The facility's equipment to eliminate the excreta, waste, and used bedding from the gutter was not working properly at the time of inspection. There was a large buildup of excreta, waste, used bedding and water under the enclosures of animals located over the south gutter of the facility. This buildup of material created a strong ammonia smell and foul odor within the facility and a large number of small black flies were present in the middle room of the facility. This buildup of material and foul odors can cause sickness in animals and attract pests such as flies. Eliminate the excessive buildup of excreta, waste, used bedding and excess soiled water from the facility as often as necessary to minimize vermin infestation, odors, and disease hazards.

Note: The licensee reports having contacted the repairman prior to inspection and contacted the repairman during the inspection and scheduled repairs for Sunday 6/26/2016. The licensee must ensure that it is fixed by then. If the equipment breaks down again, additional methods must be used to remove soiled material from the building to protect the animals from excessive odors and disease hazards.

3.130 **REPEAT**

WATERING.

The water lines that provide water for the majority of the animals have sections where the tubing has a greenish appearance. The outside of the watering line continues to have some areas where an excessive buildup of hair and soiled material is present. At least one watering bottle had a greenish buildup inside of it. Unclean water receptacles may contaminate the water supply and cause many animals to get sick. To protect the health of the animals, clean and/or replace water lines, spouts, and bottles as often as necessary to assure a clean supply of water to the animals.

3.131 (a) **REPEAT**

SANITATION.

Enclosures in the front room in the middle group pens where about 20 chinchillas are housed and enclosures on the stacked enclosures on the south side of the front room housing approximately 10 chinchillas were noted to have an excessive amount of feces. The licensee stated that the enclosures had

Prepared By:

(b) (6), (b) (7)(C)

SCOTT M WELCH, VMO USDA, APHIS, Animal Care

Date:

Title: VETERINARY MEDICAL OFFICER Inspector 6046

Jul-08-2016

Received By:

DAN MOULTON; OWNER

Date:

Title: CERTIFIED MAIL 7015 3430 0000 1868 5663

Jul-08-2016



Inspection Report

not been cleaned out in about two and a half weeks. Excessive accumulations of feces can increase animals' risks for disease and does not provide for their comfort. Enclosures must be cleaned out as often as necessary to minimize excessive accumulations of feces and soiled bedding.

Exit interview conducted with facility representative by VMO Welch and ACI Wilken.

Prepared By:

(b) (6), (b) (7)(C)

SCOTT M WELCH, VMO USDA, APHIS, Animal Care

Date:

Title: VETERINARY MEDICAL OFFICER Inspector 6046

Jul-08-2016

Received By:

DAN MOULTON; OWNER

Date:

Title: CERTIFIED MAIL 7015 3430 0000 1868 5663

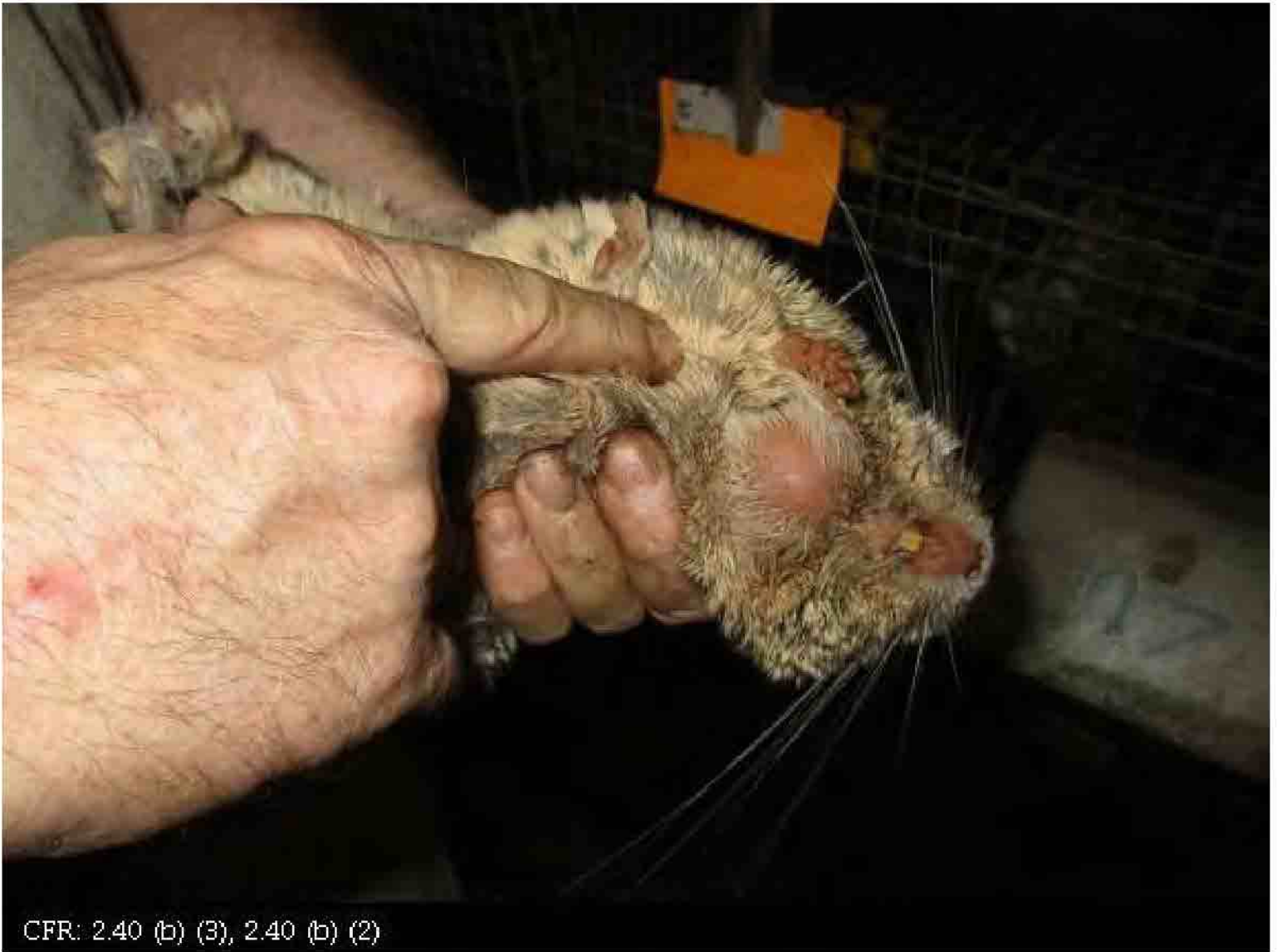Jul-08-2016



Animals Inspected at Last Inspection

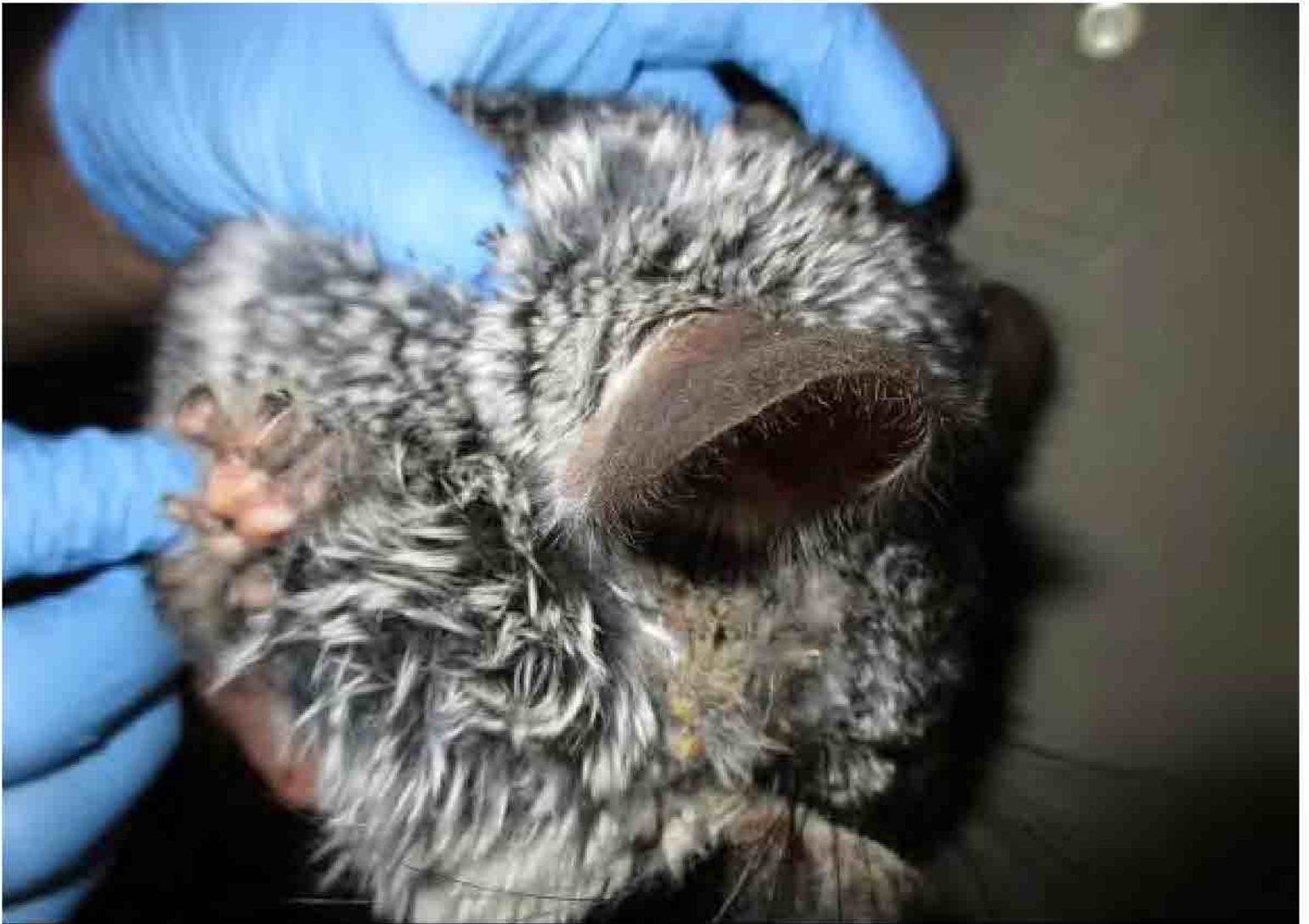
Cust No	Cert No	Site	Site Name	Inspection
2401	41-B-0239	001	DAN MOULTON	Jun-22-16

Count Species
000770 CHINCHILLA



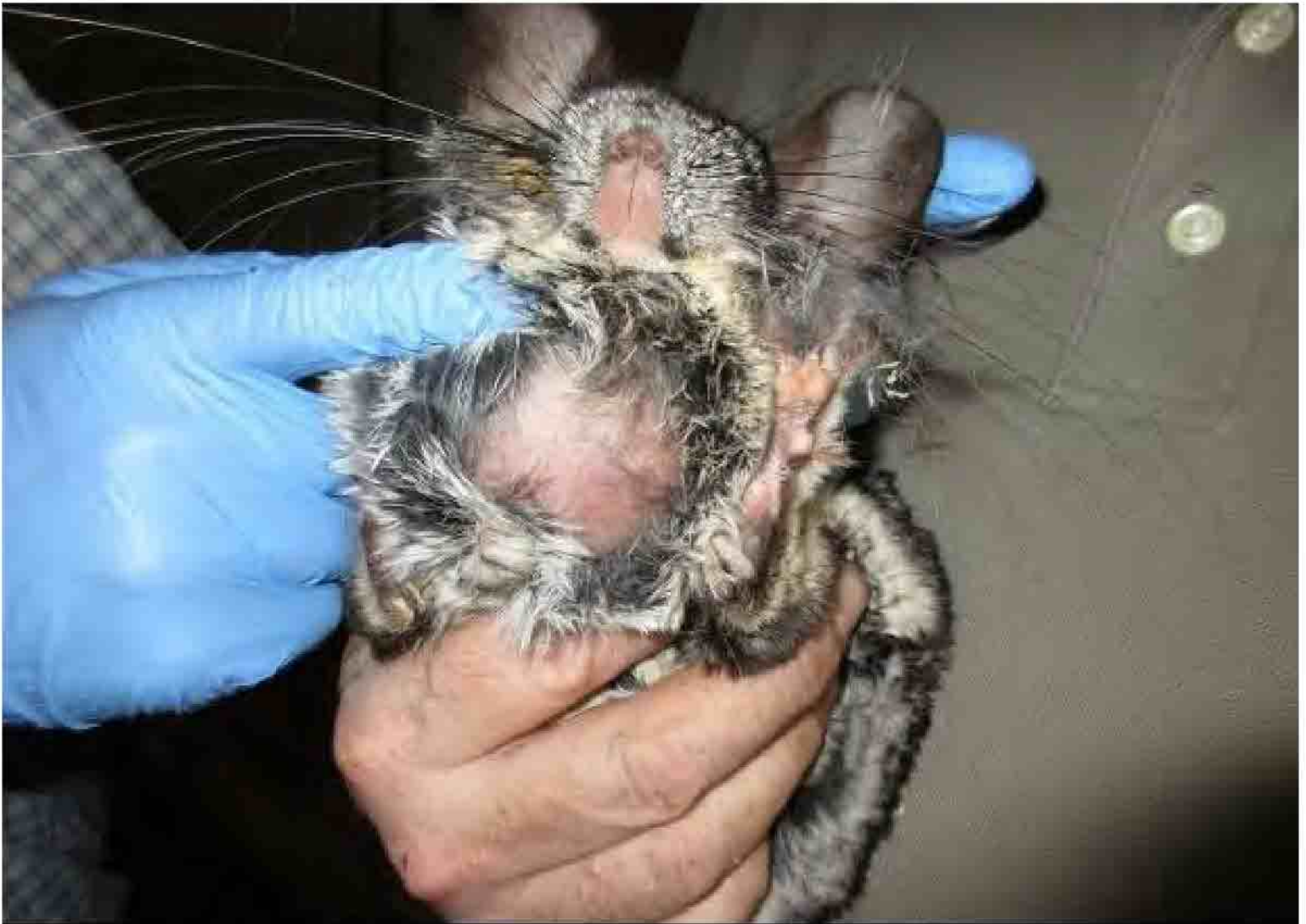CFR: 2.40 (b) (3), 2.40 (b) (2)

Photographer:	Kevin Wilken	Legal Name:	41-B-0239
Photo Taken:	Wed, Jun 22, '16	DAN MOULTON	
Inspection:	181161057380243		
Description:	Female beige, eartag GROS 352; hairless swelling under chin.		



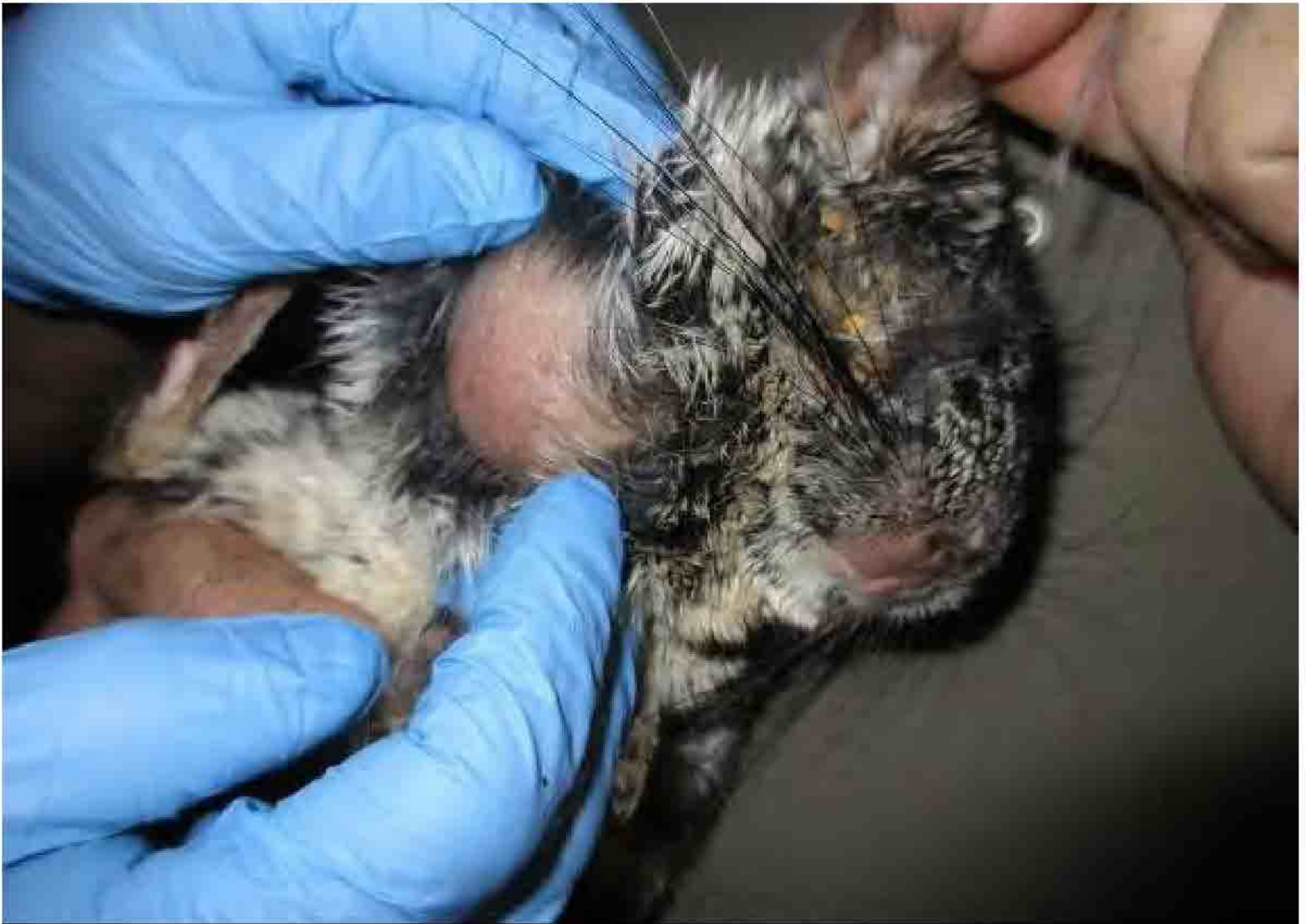CFR: 2.40 (b) (2), 2.40 (b) (3)

Photographer:	Kevin Wilken	Legal Name:	41-B-0239
Photo Taken:	Wed, Jun 22, '16	DAN MOULTON	
Inspection:	181161057380243		
Description:	Male grey (no id, in south stacked cages, west/front room); its right eye can't be seen because it is crusted shut.		



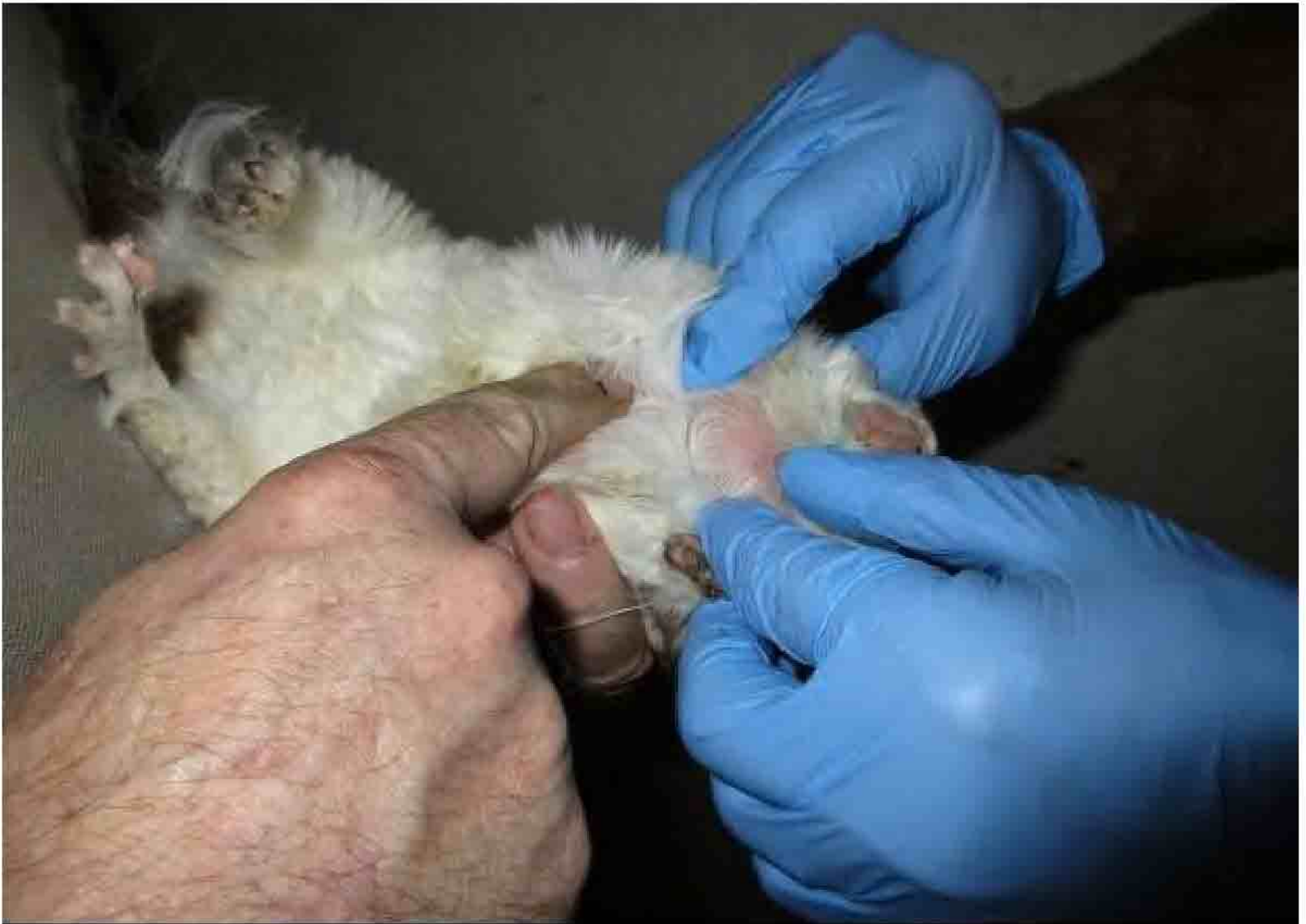CFR: 2.40 (b) (2), 2.40 (b) (3)

Photographer:	Kevin Wilken	Legal Name:	41-B-0239
Photo Taken:	Wed, Jun 22, '16	DAN MOULTON	
Inspection:	181161057380243		
Description:	Male grey (no id in south stacked cages, west/front room); large hairless swelling under chin and note its right eye crusted over.		



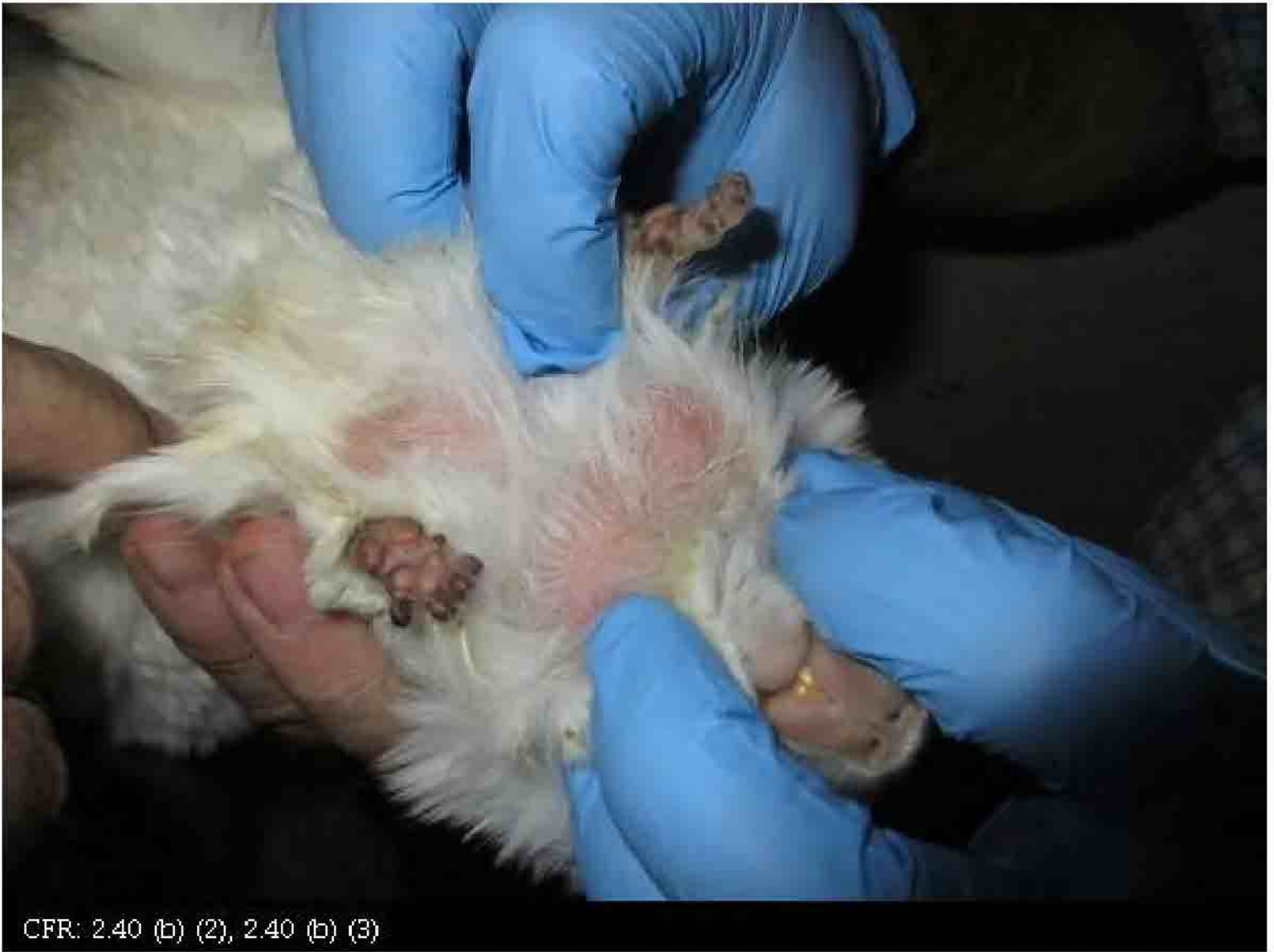CFR: 2.40 (b) (2), 2.40 (b) (3)

Photographer:	Kevin Wilken	Legal Name:	41-B-0239
Photo Taken:	Wed, Jun 22, '16	DAN MOULTON	
Inspection:	181161057380243		
Description:	Male grey (no id in south stacked cages, west/front room); large hairless swelling under chin and note its right eye crusted over.		



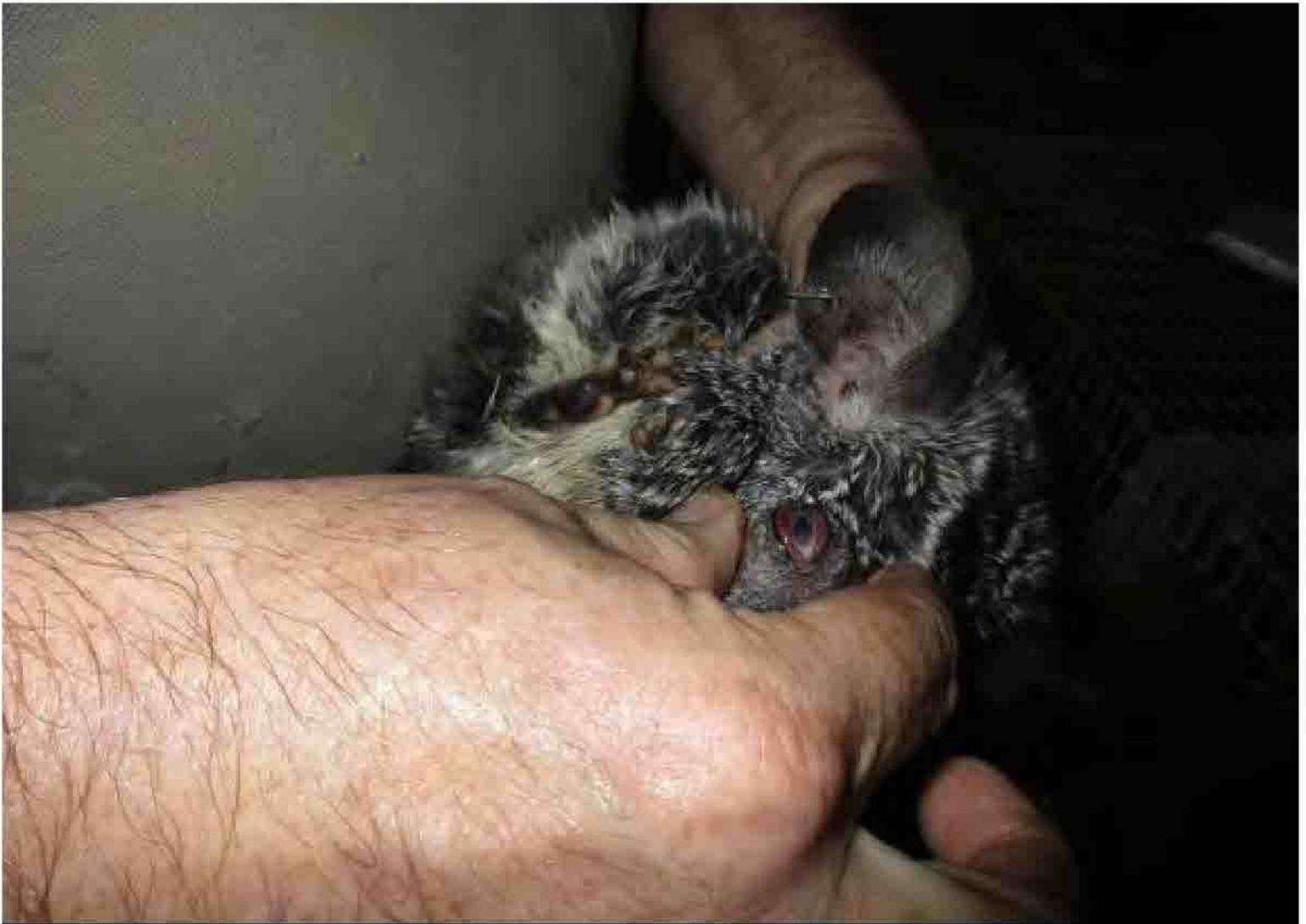CFR: 2.40 (b) (3), 2.40 (b) (2)

Photographer:	Kevin Wilken	Legal Name:	41-B-0239
Photo Taken:	Wed, Jun 22, '16	DAN MOULTON	
Inspection:	181161057380243		
Description:	White female in cage 168, ear tag 876; swollen area with hair loss under chin. Tissues felt thickened to VMO (gloved hands).		



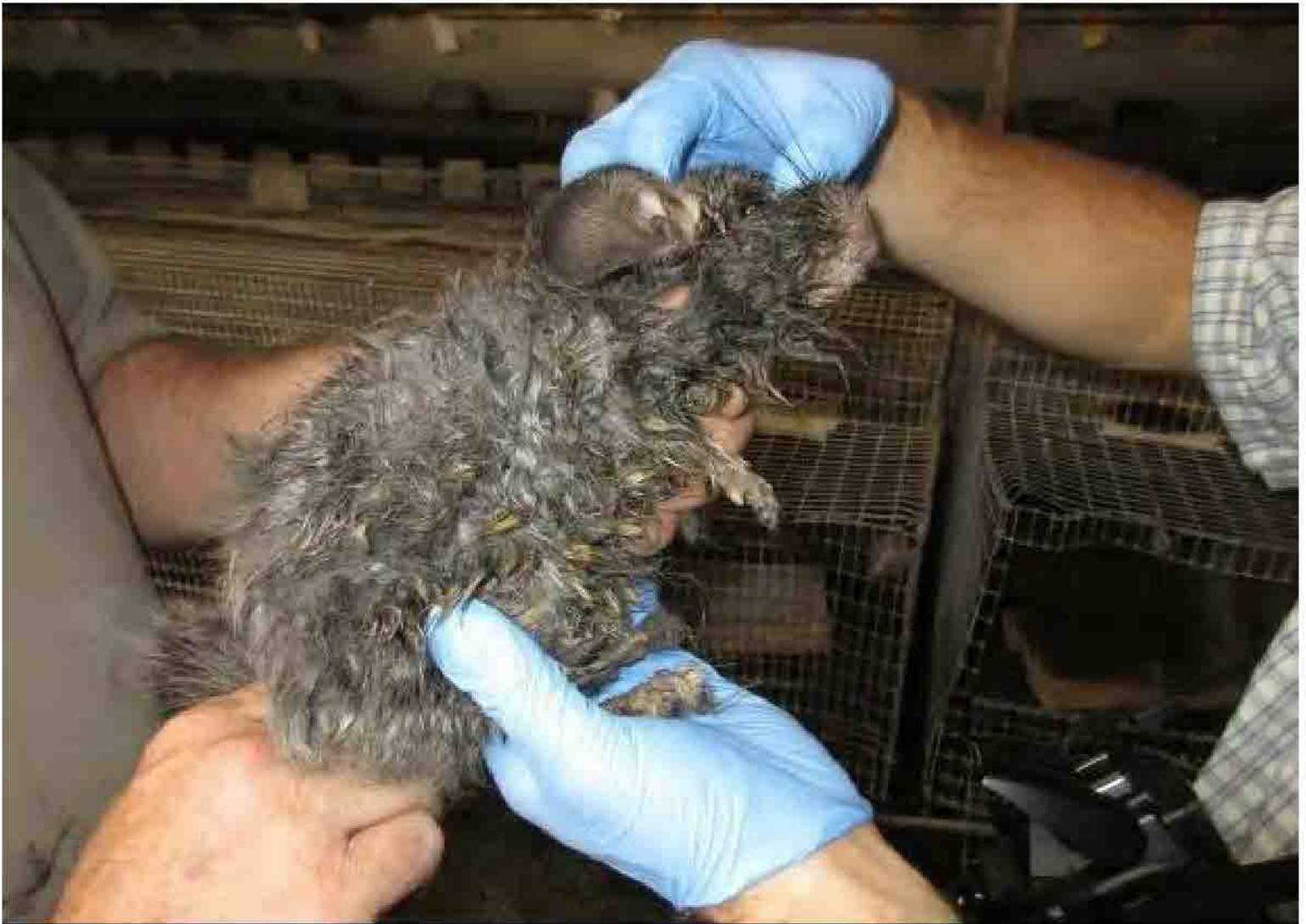CFR: 2.40 (b) (2), 2.40 (b) (3)

Photographer:	Kevin Wilken	Legal Name:	41-B-0239
Photo Taken:	Wed, Jun 22, '16	DAN MOULTON	
Inspection:	181161057380243		
Description:	White female in cage 168, ear tag 876; swollen area with hair loss under chin. Tissues felt thickened to VMO (gloved hands).		



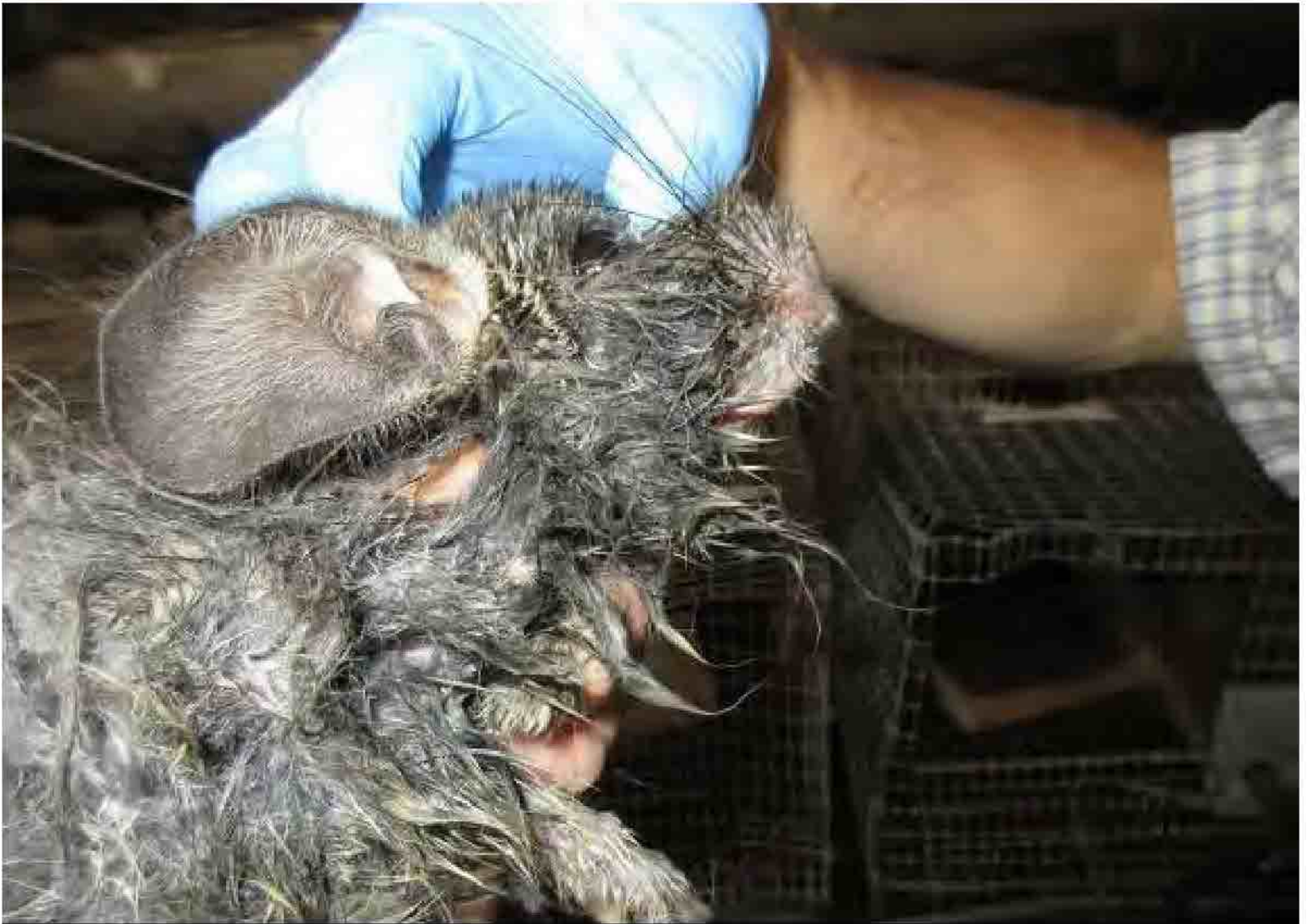CFR: 2.40 (b) (3), 2.40 (b) (2)

Photographer:	Kevin wilken	Legal Name:	41-B-0239
Photo Taken:	Wed, Jun 22, '16	DAN MOULTON	
Inspection:	181161057380243		
Description:	Female grey-- ear tag 332; its right eye is swollen and had a pale creamy discharge.		



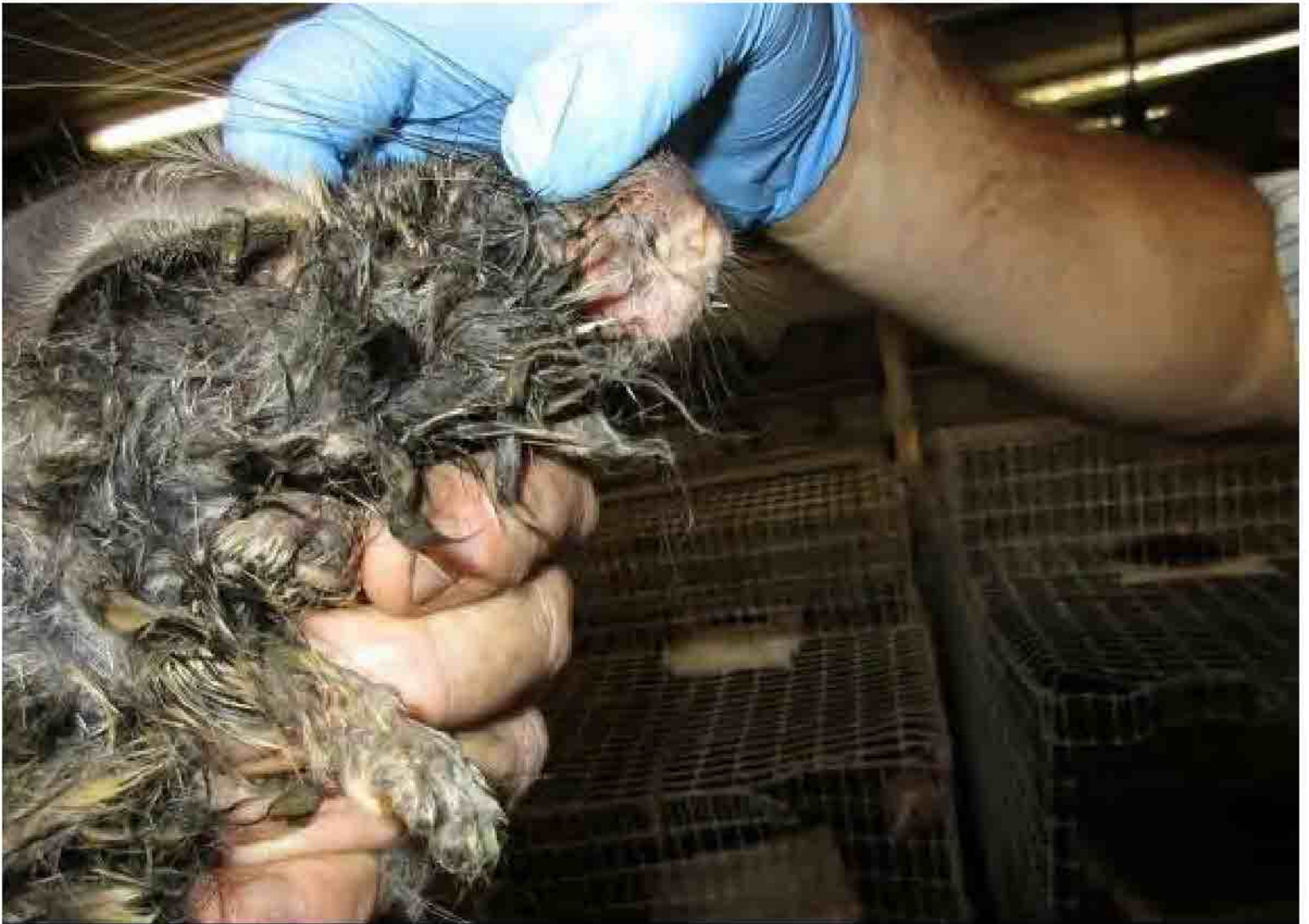CFR: 2.40 (b) (2), 2.40 (b) (3)

Photographer:	Kevin Wilken	Legal Name:	41-B-0239
Photo Taken:	Wed, Jun 22, '16	DAN MOULTON	
Inspection:	181161057380243		
Description:	Female black; eartag GROS 313; note unkempt hair coat.		



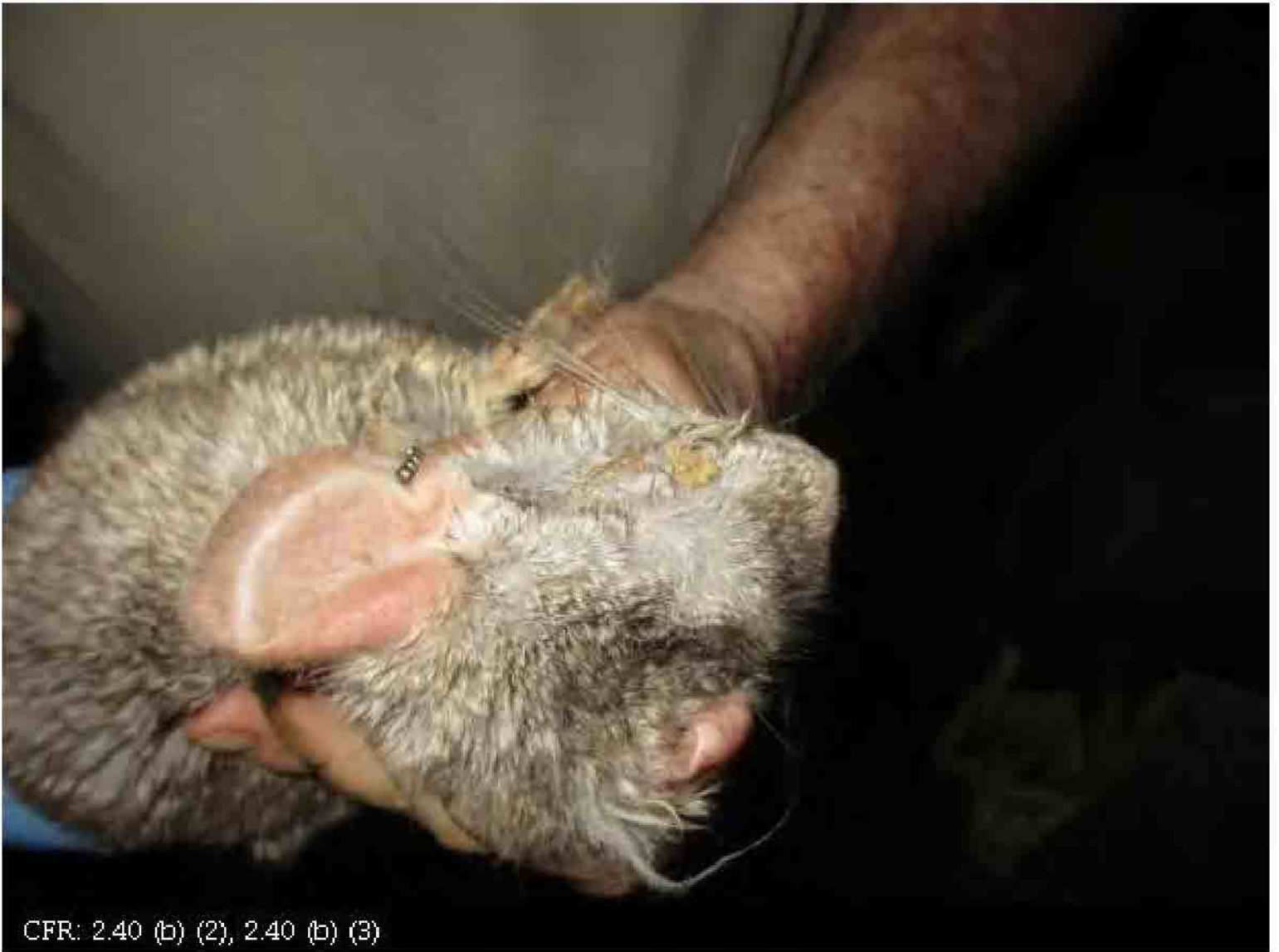CFR: 2.40 (b) (2), 2.40 (b) (3)

Photographer:	Kevin Wilken	Legal Name:	41-B-0239
Photo Taken:	Wed, Jun 22, '16	DAN MOULTON	
Inspection:	181161057380243		
Description:	Female black; eartag GROS 313; note unkempt hair coat and hair loss around mouth		



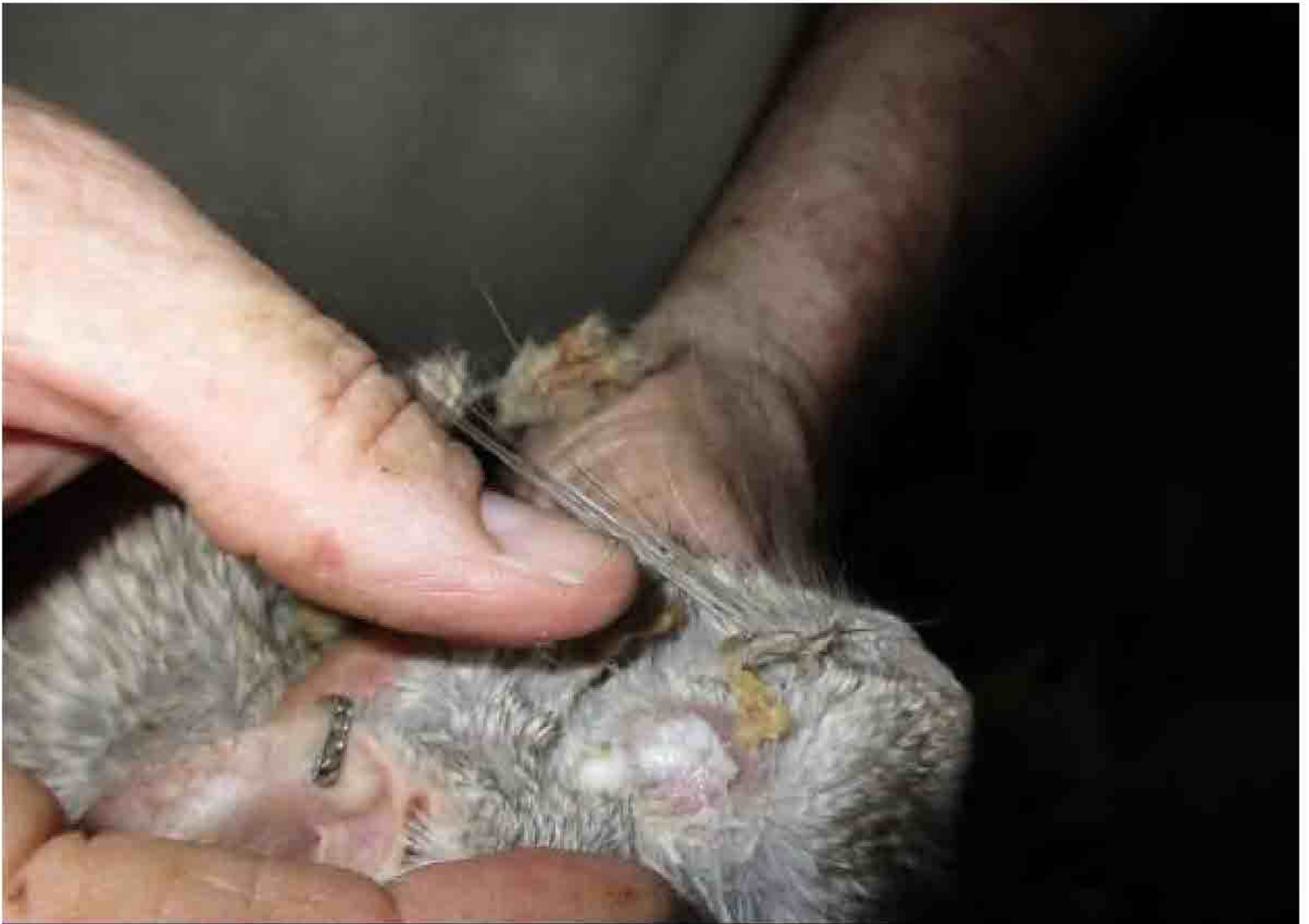CFR: 2.40 (b) (2), 2.40 (b) (3)

Photographer:	Kevin Wilken	Legal Name:	41-B-0239
Photo Taken:	Wed, Jun 22, '16	DAN MOULTON	
Inspection:	181161057380243		
Description:	Female black; eartag GROS 313; note unkempt hair coat and hair loss around mouth.		



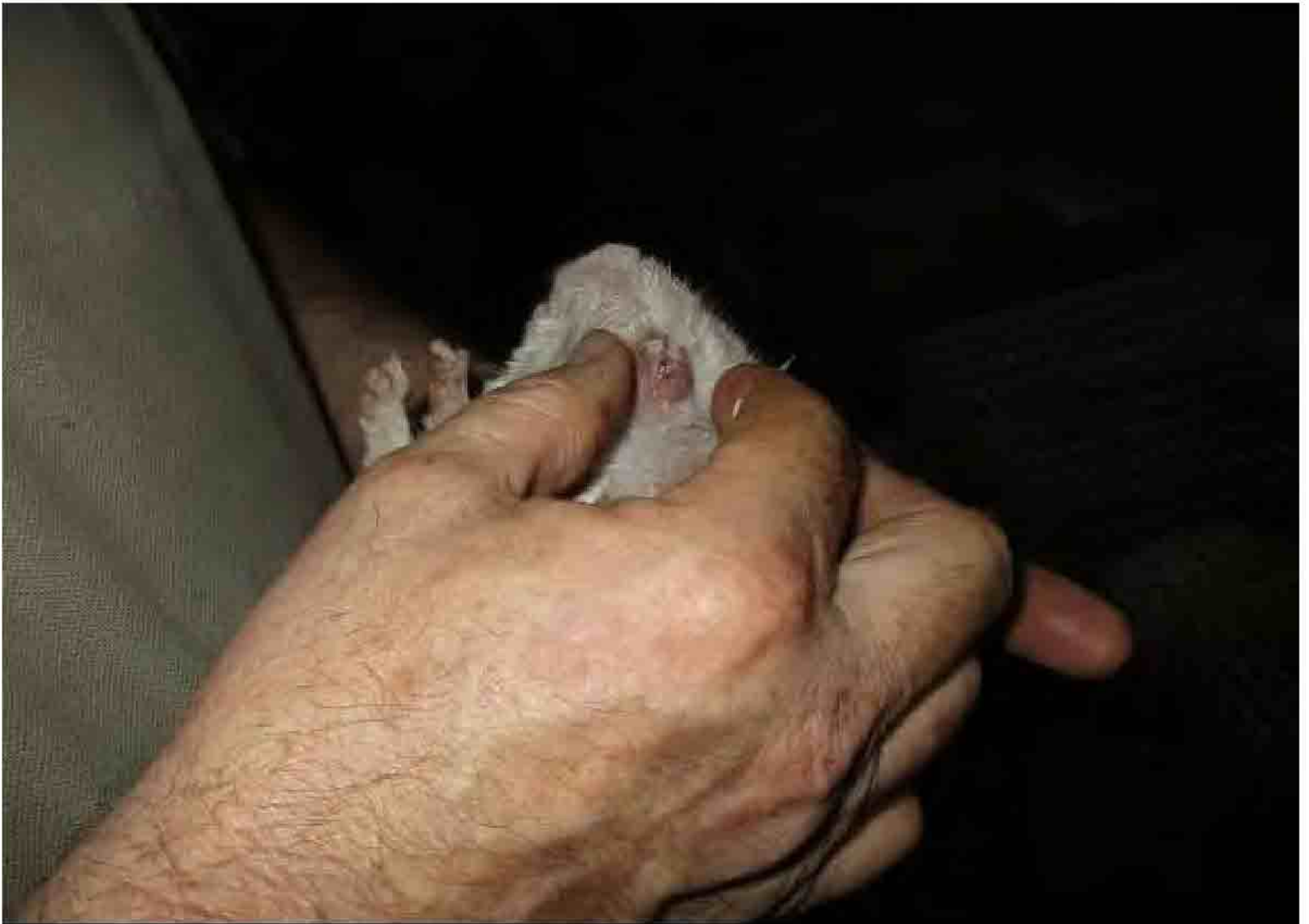CFR: 2.40 (b) (2), 2.40 (b) (3)

Photographer:	Kevin Wilken	Legal Name:	41-B-0239
Photo Taken:	Wed, Jun 22, '16	DAN MOULTON	
Inspection:	181161057380243		
Description:	Male beige with eartag GROS 329; its left eye was swollen and a pale creamy discharge.		



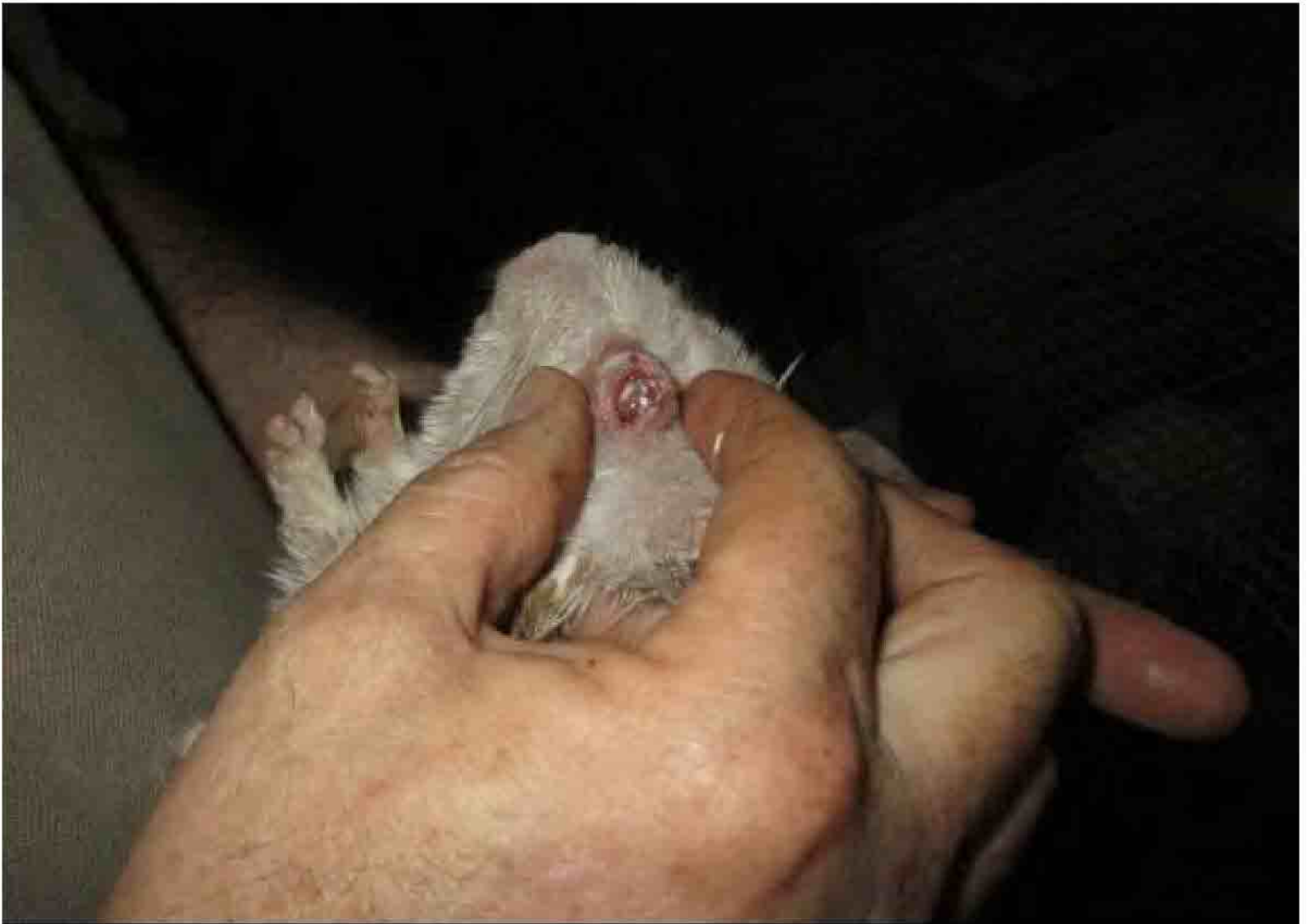CFR: 2.40 (b) (2), 2.40 (b) (3)

Photographer:	Kevin Wilken	Legal Name:	41-B-0239
Photo Taken:	Wed, Jun 22, '16	DAN MOULTON	
Inspection:	181161057380243		
Description:	Male beige with eartag GROS 329; its left eye was swollen and a pale creamy discharge.		




CFR: 2.40 (b) (3), 2.40 (b) (2)

Photographer:	Kevin Wilken	Legal Name:	41-B-0239
Photo Taken:	Wed, Jun 22, '16	DAN MOULTON	
Inspection:	181161057380243		
Description:	Male beige (no ID; cage card AMMC); note left eye swollen with pale creamy discharge.		



CFR: 2.40 (b) (3), 2.40 (b) (2)

Photographer:	Kevin Wilken	Legal Name:	41-B-0239
Photo Taken:	Wed, Jun 22, '16	DAN MOULTON	
Inspection:	181161057380243		
Description:	Male beige (no ID; cage card AMMC); note left eye swollen with pale creamy discharge.		



CFR: 2.40 (b) (3), 2.40 (b) (2)

Photographer:	Kevin Wilken	Legal Name:	41-B-0239
Photo Taken:	Wed, Jun 22, '16	DAN MOULTON	
Inspection:	181161057380243		
Description:	Female grey with eartag PMR 233; its left eyeball was noted to have an opaque mass inside it.		



CFR: 2.40 (b) (2)

Photographer:	Scott Welch	Legal Name:	41-B-0239
Photo Taken:	Wed, Jun 22, '16	DAN MOULTON	
Inspection:	181161057380243		
Description:	Silver grey female (no ID, housed in front room, north side, cages facing the wall); head tilted to the left.		



CFR: 2.40 (b) (2)

Photographer:	Scott Welch	Legal Name:	41-B-0239
Photo Taken:	Wed, Jun 22, '16	DAN MOULTON	
Inspection:	181161057380243		
Description:	Silver grey female (no ID, housed in front room, north side, cages facing the wall); head tilted to the left.		



CFR: 3.131 (a)

Photographer:	Kevin Wilken	Legal Name:	41-B-0239
Photo Taken:	Wed, Jun 22, '16	DAN MOULTON	
Inspection:	181161057380243		
Description:	Enclosure in front room, south side; representative of enclosures with excessive feces and soiled material.		



CFR: 3.131 (a)

Photographer:	Kevin Wilken	Legal Name:	41-B-0239
Photo Taken:	Wed, Jun 22, '16	DAN MOULTON	
Inspection:	181161057380243		
Description:	Front room middle pen, excessive feces.		



CFR: 3.131 (a)

Photographer:	Kevin Wilken	Legal Name:	41-B-0239
Photo Taken:	Wed, Jun 22, '16	DAN MOULTON	
Inspection:	181161057380243		
Description:	Enclosure in front room, south side; representative of enclosures with excessive feces and soiled material.		



CFR: 3.131 (a)

Photographer:	Kevin Wilken	Legal Name:	41-B-0239
Photo Taken:	Wed, Jun 22, '16	DAN MOULTON	
Inspection:	181161057380243		
Description:	Front room middle row pen, excessive feces.		



CFR: 3.131 (a)

Photographer:	Kevin Wilken	Legal Name:	41-B-0239
Photo Taken:	Wed, Jun 22, '16	DAN MOULTON	
Inspection:	181161057380243		
Description:	Front room middle row pen, excessive feces.		




CFR: 3.130

Photographer:	Kevin Wilken	Legal Name:	41-B-0239
Photo Taken:	Wed, Jun 22, '16	DAN MOULTON	
Inspection:	181161057380243		
Description:	Water bottle with greenish buildup inside.		



CFR: 3.131 (a)

Photographer:	Kevin Wilken	Legal Name:	41-B-0239
Photo Taken:	Wed, Jun 22, '16	DAN MOULTON	
Inspection:	181161057380243		
Description:	Front room middle row pen, excessive feces.		



Photographer:	Scott Welch	Legal Name:	41-B-0239
Photo Taken:	Wed, Jun 22, '16	DAN MOULTON	
Inspection:	181161057380243		
Description:	Water line facing north wall with greenish build-up inside.		




CFR: 3.130

Photographer:	Scott Welch	Legal Name:	41-B-0239
Photo Taken:	Wed, Jun 22, '16	DAN MOULTON	
Inspection:	181161057380243		
Description:	Water line; front room, stacked cages on south wall.		



CFR: 3.130

Photographer:	Scott Welch	Legal Name:	41-B-0239
Photo Taken:	Wed, Jun 22, '16	DAN MOULTON	
Inspection:	181161057380243		
Description:	Water line; front room, stacked cages on south wall.		



CFR: 3.125 (d)

Photographer:	Scott Welch	Legal Name:	41-B-0239
Photo Taken:	Wed, Jun 22, '16	DAN MOULTON	
Inspection:	181161057380243		
Description:	Build up of soiled material in south gutter of facility; picture taken in middle room looking northwest.		



CFR: 3.125 (d)

Photographer:	Scott Welch	Legal Name:	41-B-0239
Photo Taken:	Wed, Jun 22, '16	DAN MOULTON	
Inspection:	181161057380243		
Description:	Build up of soiled material in south gutter of facility; picture taken in middle room looking east.		



CFR: 3.125 (a)

Photographer:	Scott Welch	Legal Name:	41-B-0239
Photo Taken:	Wed, Jun 22, '16	DAN MOULTON	
Inspection:	181161057380243		
Description:	Piece of broken panel with sharp wire points; similar piece is present in enclosure to left white chinchilla and noted in bottom left of photo.		



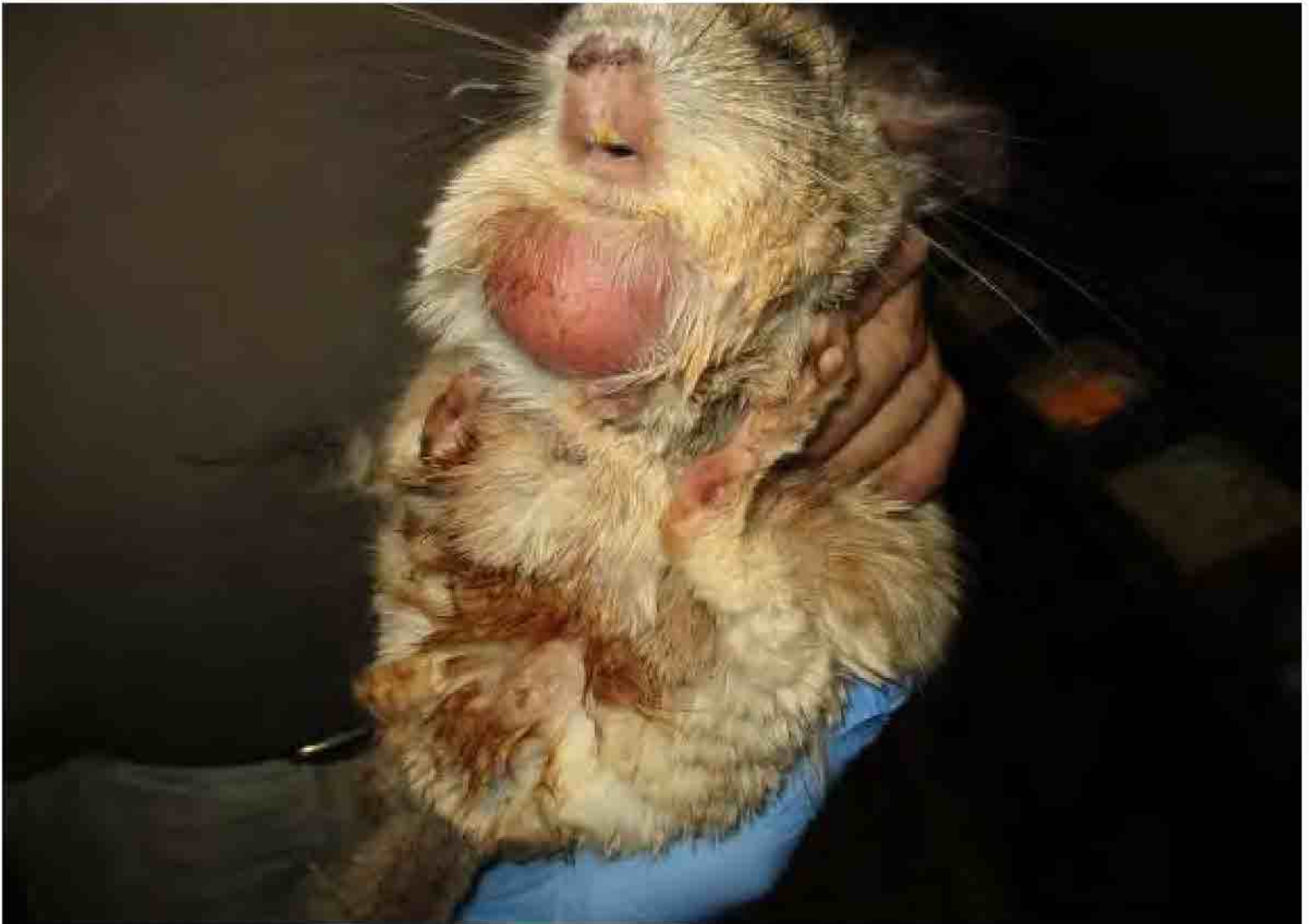CFR: 3.130

Photographer:	Scott Welch	Legal Name:	41-B-0239
Photo Taken:	Wed, Jun 22, '16	DAN MOULTON	
Inspection:	181161057380243		
Description:	Wire points removed from two affected cages; however, note soiled water-line with hair and soiled material on it.		



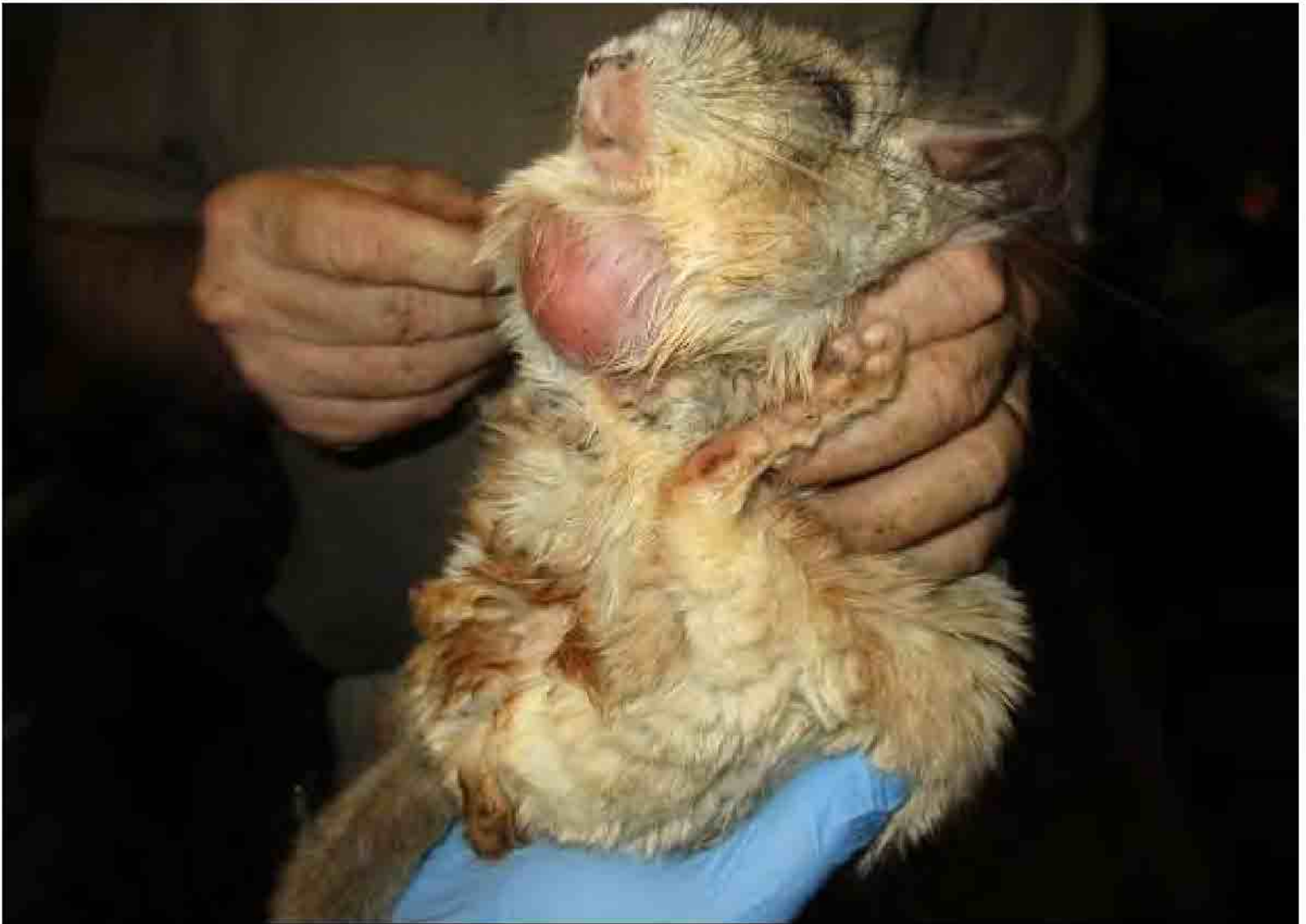CFR: 3.130

Photographer:	Scott Welch	Legal Name:	41-B-0239
Photo Taken:	Wed, Jun 22, '16	DAN MOULTON	
Inspection:	181161057380243		
Description:	Wire points removed from two affected cages; however, note soiled water-line with hair and soiled material on it (towards bottom of photo).		



CFR: 2.40 (b) (2), 2.40 (b) (3)

Photographer:	Kevin Wilken	Legal Name:	41-B-0239
Photo Taken:	Wed, Jun 22, '16	DAN MOULTON	
Inspection:	181161057380243		
Description:	Male cream eartag GROS 375; large reddened hairless swelling under chin.		



CFR: 2.40 (b) (3), 2.40 (b) (2)

Photographer:	Kevin Wilken	Legal Name:	41-B-0239
Photo Taken:	Wed, Jun 22, '16	DAN MOULTON	
Inspection:	181161057380243		
Description:	Male cream eartag GROS 375; large reddened hairless swelling under chin.		